

Primary sacral lymphoma initially supposed to be sacroiliitis on bone scintigraphy

Kürşat Okuyucu(*), Engin Alagöz(*), Şükrü Özaydın(*), Ümüt Güzelkücük(**), Nuri Arslan(***)

ÖZET

Kemik sintigrafisinde başlangıçta sakroiliitisi düşündüren primer sakral lenfoma

Primer kemik lenfoması Non Hodgkin lenfomanın nadir bir türü olup sakrum bu hastalık için atipik bir tutulum yeridir. Benign ve diğer malign kemik hastalıkları ile karıştırılabilmektedir. Biz burada Tc-99m MDP kemik sintigrafisinde görülen sakrum yerleşimli bir primer kemik lenfoması vakasını takdim ediyoruz.

Anahtar Kelimeler: Primer kemik lenfoması, sakroileit, Tc-99m MDP kemik sintigrafisi

SUMMARY

Primary bone lymphoma is a rare kind of non-Hodgkin lymphoma and sacrum is an atypical location for this disease. It may be confused with benign and other malignant bone pathologies. Here we report a case of primary sacral bone lymphoma settled in sacrum encountered on Tc-99m MDP bone scintigraphy.

Key words: Primary bone lymphoma, sacroiliitis, Tc-99m MDP bone scintigraphy

Introduction

Primary bone lymphoma (PBL) is an extranodal lymphoma and manifests as a localized solitary lesion forming approximately 3% of all malignant bone tumours, nearly 7% of extranodal lymphomas, 1% of all malignant lymphomas (1). It is a rare pathology arising from the medullar cavity of a unique bone without regional lymph node or visceral involvement (2). Any part of the skeleton can be involved, though it tends to lodge in long bones. Femur shaft is the prime site (50%), pelvis is the second (2). Imaging features are generally not uniform. It has various radiologic findings (3). Although sclerotic and mixed osteolytic/osteosclerotic foci may be seen, osteolysis is the most common (4).

Case

A 70 year-old woman had been suffering from hip pain referring to leg for last three months without fever, nocturnal sweating and weight loss. She had degenerative changes on lumbosacral x-ray graphy. There was no evidence leading to a specific diagnosis with physical examination and laboratory tests. The patient was considered to be affected by sacroiliitis and a whole-body bone scintigraphy was requested. On whole-body scan, irregular sacral and left sacroiliac joint activity was observed. A primary malignant bone tumour was thought firstly for differential diagnosis taking into account her age. In contrast-enhanced CT (CECT), a soft tissue mass causing bone destruction was noticed at left sacroiliac joint area. The patient was diagnosed histopathologically as diffuse large B-cell lymphoma originating from sacrum. There were markedly increased uptake (SUV max:7.49) at sacrum, sacroiliac joint and sacral plexus on FDG-PET scan.

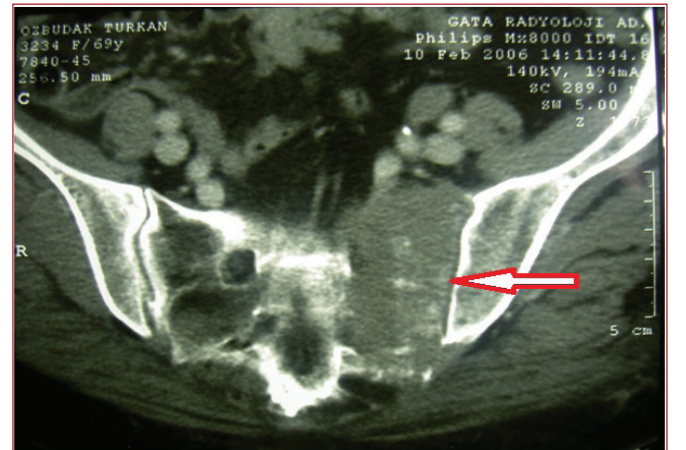


Figure 1: A soft tissue mass causing bone destruction was noticed at left sacroiliac joint area (arrow) on transaxial slice of CECT.

*Department of Medical Oncology, Gülhane Medical Faculty Ankara, Turkey.

**Department of Physical Medicine and Rehabilitation, Bilkent Veterans Rehabilitation Center, Ankara, Turkey.

***Department of Nuclear Medicine, Gülhane Medical Faculty Ankara, Turkey

Ayrı Basım İsteği: Engin alagöz

Department of Nuclear Medicine, Gülhane Medical Faculty, Ankara, Turkey.

E-Mail: ealagöz@Gulhanemedicaljournal.org

Makalenin Geliş Tarihi: Jun 29, 2015 • Kabul Tarihi: Sep 07, 2015 • Çevrim İçi Basım Tarihi: 30 Eylül 2016

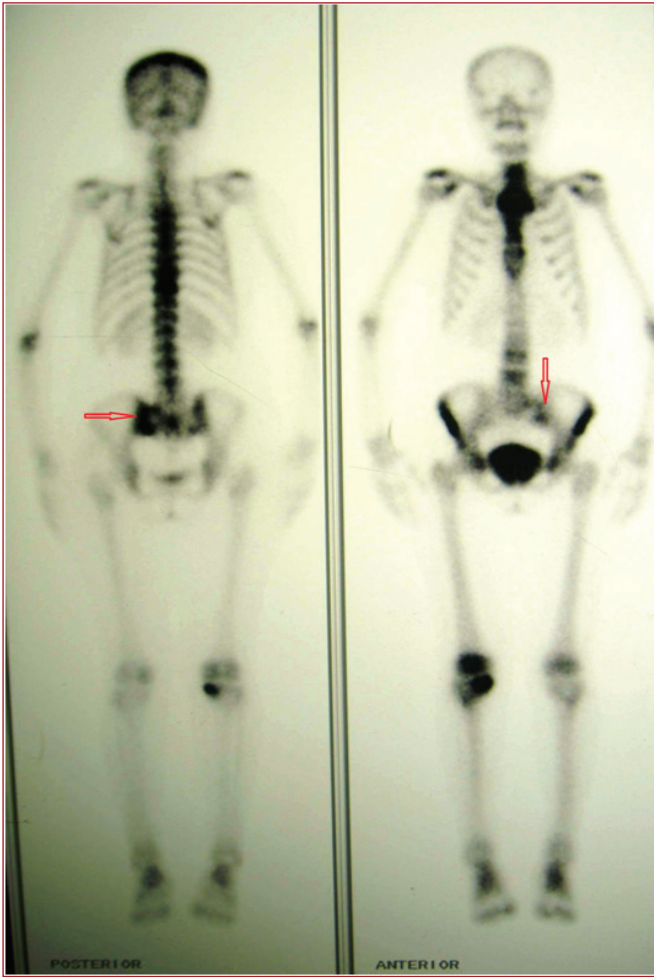


Figure 2: Anterior and posterior whole-body MDP bone scintigraphy showed irregular sacral and left sacroiliac joint activity (arrows).

Discussion

In this case with PBL, the contributions of bone scintigraphy, plain x-ray, CT, MRI, FDG-PET findings to diagnosis and patient management is presented. As PBL is a curable entity and has nonspecific imaging patterns, it must be differentiated from other causes of lytic lesions such as carcinoma metastasis, primary bone tumours and various benign conditions. Common complaint is pain over the affected bone. Patients may go to rheumatologist, misdiagnosed with rheumatic disease and take nonsteroidal anti-inflammatory drugs in vain (5). Sometimes it creates severe disturbance because of a pathologic fracture. Initial plain x-ray is usually normal. Solitary lytic lesion arouses doubt. But this appearance is not specific. In the same way, radionuclide bone scintigraphy shows nonspecific high tracer uptake (6). However, scintigraphy is valuable in staging, it can detect multifocal involvement which alters therapy (7). CT delineates cortical destruction and bone remodelling after treatment. MRI is more effective in diagnosis showing soft tissue masses, abnormal marrow lesions without cortical findings. PBL usually comes out with hypermetabolic appearance on FDG-PET which is a valuable tool especially for determining response to treatment (8). As mentioned above all imaging methods have different properties complementing each other that should be benefited from for diagnosis and handled in manipulation of ambiguous lesions ran into on classical imaging techniques.

Conclusion

Meticulous elaboration of localized nonspecific osteoblastic activity increases by attentively correlating them clinically and radiologically, especially at areas where degenerative and inflammatory bone diseases are frequently encountered will preclude escaping of a more serious illness such as a malignancy that absolutely threatens life. On the other hand, FDG-PET imaging contributes remarkably to the supporting of lymphoma diagnosis and more accurate staging of it.

References

1. Singh T, Satheesh CT, Lakshmaiah KC. Primary bone lymphoma: A report of two cases and review of the literature. *J Cancer Res Ther.* 2010;6:296-298.
2. Zhou HY, Gao F, Bu B. Primary bone lymphoma: A case report and review of the literature. *Oncol Lett.* 2014 Oct;8(4):1551-1558.
3. Resnick D, Lymphomas. In: D Resnick, Editor, *Diagnosis of bone and joint disorders* (3rd edition). Saunders, Philadelphia (1995), pp. 2258-2294.
4. Edeiken-Monroe B, Edeiken J, Kim EE. Radiologic concepts of lymphoma of bone. *Radiol Clin North Am.* 1990 Jul;28(4):841-864.
5. Haussler MD, Fenstermacher MJ, Johnston DA. MRI of primary lymphoma of bone: Cortical disorder as a criterion for differential diagnosis. *J Magn Reson Imaging.* 1999 Jan;9(1):93-100.
6. Prakash S, Gopinath PG, Bhargava S. Evaluation of quantitative sacroiliac scintigraphy for the early detection of sacroiliitis. *Eur J Nucl Med.* 1983;8(12): 531-534.
7. Ramadan KM, Shenker T, Sehn LH. A clinicopathologic retrospective study of 131 patients with primary bone lymphoma: a population-based study of successively treated cohorts from the British Columbia Cancer Agency. *Ann Oncol.* 2007;18:129-135.
8. Fidas P, Spiro I, Sobczak ML. Long-term results of combined modality therapy in primary bone lymphomas. *Int J Radiat Oncol Biol Phys.* 1999;45:1213-1218.