

Gemination with talon's cusp on mandibular central incisor: An unusual occurrence

Dr Renita Lorina Castelino(*), Anusha Rangare Laxmana(**), Sham Kishor Kannepady(**), Preethi Balan(***), Fazil KA(***)

ÖZET

Fetal taşikardi en iyi bilinen non-immun hidrops fetalis nedenidir. Fetal taşikardi tedavi edilmezse hidrops fetalise ve fetal kayıba neden olabilmektedir. Hidrops fetaliste prognoz antiaritmik tedaviye hızlı yanıtla, gebelik haftasına, fetusun iyilik haline ve yüksek kardiyovasküler profil skora (KVPS) bağlıdır. Biz burada SVT'ye sekonder gelişen 28 haftalık hidropslu fetusu olgu olarak sunduk. Biz KVPS'ü tartışmak amacıyla bu olgu sunumunu sunduk. Olgumuzda Digoksin ve sotalol den oluşan kombine maternal antiaritmik tedavinin 1. günde fetal taşikardinin başarılı şekilde sinüs ritmine dönüştüğü izlendi fakat fetusun iyilik hali gittikçe bozulup hidrops fetalis ağırlaştı ve tedavinin 21. günü fetal kayıp gerçekleşti. Fetusun kardiyovasküler profil skoru (KVPS) 7/10 (cilt ödemi 2 puan, duktus venozusta revers atriyal A dalgası 1 puan kayıp) idi. Ve bu yaşamla bağdaşır kabul edilebilir bir skordu. Fakat olgumuzda hayatla bağdaşır (7/10) KVPS olmasına rağmen fetal kayıp oluşmuştur. Kardiyovasküler profil skor SVT'ye sekonder gelişen hidrops fetalisin prognozunu belirlemede yanıltıcı olabilir.

Anahtar Kelimeler: *Hidrops fetalis; Fetal Taşiaritmi, Kardiyovasküler Profil Skoru*

SUMMARY

Gemination, is the attempted division of a single tooth germ by invagination during the growth cycle resulting in a bifid crown. They are found frequently in the primary than in the permanent dentition with a prevalence of approximately 1% and 0.1% respectively. It is most often seen in the maxillary primary incisors and the canines. The Talon's cusp is a relatively rare developmental anomaly characterized by the presence of an accessory cusp like structure projecting from the cingulum area of the maxillary or mandibular anterior teeth in both the primary and permanent dentition. This anomalous structure is composed of normal enamel and dentin and either has pulp tissue or is devoid of it. Germination of mandibular anterior teeth along with Talon's cusp is a rare phenomena and very few cases have been reported in literature. We therefore, report a rare case of germination with Talon's cusp in the mandibular central incisor with review of literature.

Key words: *Talon, gemination, twinning, double teeth, synodontia*

Introduction

A developing tooth can undergo variations and fluctuations during tooth development and can result in various developmental anomalies. It can be either in the primary or in the permanent dentition. The terms "double teeth", "double formations", "joined teeth", "fused teeth" or "dental twinning"^[1,2,3] are often used to describe the anomaly of conjoined tooth. The terms like germination, schizodontia, connation, synodontia, linking tooth^[4] have also been suggested in literature.

Gemination according to McDonald is defined as an attempted division of a single tooth bud by invagination during development^[5]. The number of teeth in the arch is usually normal and a radiograph shows one root and one pulp space with two partially or totally separated crowns. In gemination the two halves of the joined crowns are usually mirror images in contrast to fusion, which manifests with a distinct difference in the two halves of the crown as suggested by Kelly^[6]. It is mostly found in the primary dentition than permanent with prevalence of approximately 1% and 0.1% respectively in Caucasian groups^[7]. There is equal gender distribution. The aetiology is unclear. Spouge suggests that the condition may result from trauma to the developing tooth bud^[8]. Other authors suggest hereditary tendency and complex interactions among a variety of genetic and environmental factors.

Talon's cusp is also an uncommon dental anomaly in which a cusp-like structure projects from the cingulum area or cemento-enamel junction of the maxillary or mandibular anterior teeth into both primary and permanent dentitions. The anomalous structure contains enamel, dentin with or without pulp tissue^[9]. Talon's cusp is very rare anomaly, especially when it occurs on mandibular teeth^[10]. There is equal gender distribution and can occur either unilaterally or bilaterally. The permanent dentition is more often affected than the primary dentition; the maxillary lateral incisor being the most frequently involved teeth in the permanent dentition and maxillary central incisor in the primary dentition.

The aetiology of the Talon's cusp remains unknown, but seems to have both genetic and environmental components. It is believed that the Talon's cusp originates during the morpho-differentiation stage of tooth development, where it may occur as a result of the outward folding of the inner enamel epithelial cells, and transient focal hyperplasia of the peripheral cells of the mesenchymal dental papilla^[9]. Talon's cusp on a geminated tooth is a very rare phenomenon and only few cases have been reported to date in literature. As per the literature only 14 cases of Talon's cusp on mandibular incisors have been reported so far with 2 being on the left central incisor^[11]. The

*A B Shetty Memorial Institute of Dental Sciences Nitte University.

**Century International Institute Of Dental Sciences And Research Centre.

***A B Shetty Memorial Institute of Dental Sciences Nitte University.

Ayrı Basım İsteği: Renita L. Castelino, Lorina Castelino
A B Shetty Memorial Institute of Dental Sciences Nitte University.
e-mail: renita.castelino@yahoo.com

Makalenin Geliş Tarihi: Jun 25, 2014 • Kabul Tarihi: Oct 11, 2014 • Çevrim İçi Basım Tarihi: 18 Mart 2016

case reported here highlights yet another case of Talon's cusp on mandibular left central incisor along with germination which is a rare occurrence.

Case report

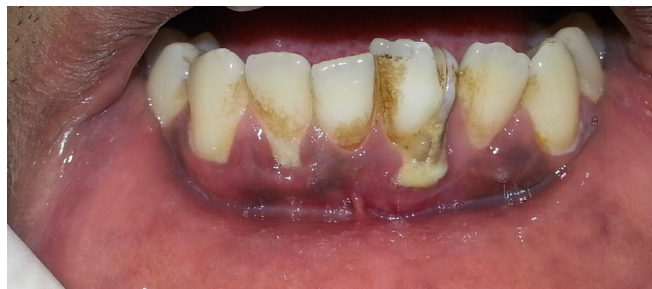

Figure 1: Labial aspect of rotated geminated mandibular left incisor

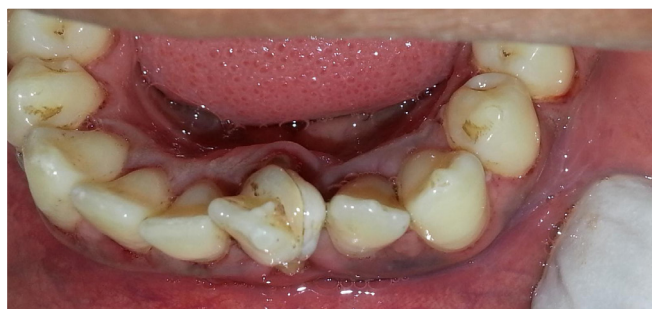

Figure 2: Incisal aspect of geminated mandibular left incisor with Talon's cusp

A 24 year old male patient reported to the Department of Oral Medicine and Radiology with the complaint of deposits in all teeth since six months with no associated symptoms. The patient was well built and nourished. On intra oral examination, the gingiva was marginally inflamed along with recession on mandibular left central incisor and mandibular right lateral incisor. Stains were also noted on all teeth. The tooth number 31 was conjoined with partially separated crowns and slightly rotated on the labial aspect [Figure 1].

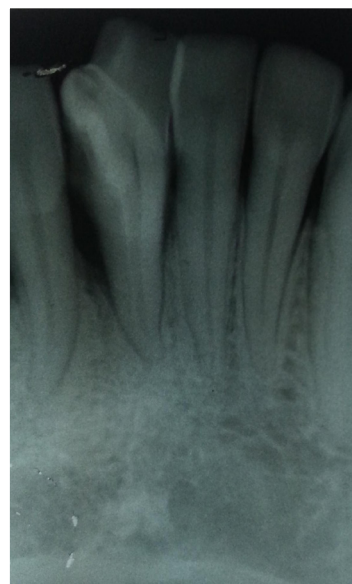


Figure 3: Intra oral periapical radiograph of geminated mandibular left incisor with the Talon's cusp

The lingual examination revealed a projection resembling Talon's cusp just below the incisal tip and it appeared to be joined to the other crown which was attached to 31 [Figure 2]. Non-carious developmental grooves were present at the junction of the Talon's cusp and the lingual surface of the tooth. The patient's family history was non contributory. The affected tooth responded normally to electric and thermal pulp tests. A missing tooth in relation to upper central incisor was also noticed. There was also crowding present in the lower anterior region.

The number of teeth remained unaffected in the mandibular arch. Based on these findings a provisional diagnosis of chronic generalised gingivitis with localised periodontitis in relation to 31 and 42 and gemination along with talon's cusp on 31 was considered. The patient had also Angle's class I malocclusion with crowding of lower anterior teeth. An intra oral periapical radiograph was taken in relation to 31 which revealed the presence of a partially separated tooth superimposed on the mandibular left central incisor giving it a bifid crown appearance with single enlarged pulp chamber and one root. The radiopaque V shaped structure above the partially separated tooth suggestive of Talon's cusp. There was horizontal bone loss present interdentally [Figure 3].

As a part of treatment, a thorough oral prophylaxis, root planing and prosthetic rehabilitation of the missing tooth was carried out. The patient was advised intentional root canal treatment followed by crown placement for the affected tooth due to aesthetic concerns but the patient was not willing. The geminated tooth had no caries and the patient was kept on a follow up for two years to check for any development of caries as such teeth are more prone to decay due to the presence of developmental grooves.

Discussion:

The development of tooth is a continuous process in which a number of physiological and morphological stages interplay to give a final form and shape to the tooth [12]. Geminated teeth are developmental anomalies of tooth shape that arise from an abortive attempt by a single tooth bud to divide, resulting in a bifid crown. They are found more frequently in the primary than in the permanent dentition. Gemination is most often seen in the maxillary primary incisors and the canines. The etiology of geminated teeth remains unknown although many authors have suggested trauma and heredity [7]. Radiographically it may appear as a bifid crown with single and enlarged root canal as seen in our case. In 1979 the 'Two tooth' rule was introduced to use the term fusion and germination. If the fused teeth are considered as one and the number of teeth in the dental arch will be less, then the term fusion is considered. If the number of teeth in the dental arch is normal then it is termed as germination or it is a case of fusion between normal and supernumerary tooth. However, supernumerary tooth has a conical shape and so it shows difference in the two halves of the joined crowns [13].

Gemination can often give rise to a number of clinical problems, particularly if the anterior teeth are involved like tooth malalignment, spacing problems, arch asymmetry, unacceptable appearance, periodontal involvement and impeded the eruption of the adjacent tooth [7]. In the case presented her malalignment of tooth was noticed. The treatment of gemination are scant and inconclusive because of the rarity of the condition, particularly in the permanent dentition and the suggested treatment in literature includes division of crown with removal of one tooth and endodontically treating the tooth followed by crown placement or composite restoration [7].

On the other hand Talon's cusp, or dens evaginatus of anterior teeth, is a relatively rare developmental anomaly characterized by the presence of an accessory cusplike structure projecting from the cingulum area or cemento-enamel junction of the maxillary or mandibular anterior teeth in both the

primary and permanent dentition. This anomalous structure is composed of normal enamel and dentin with or without pulp tissue^[9]. The anomaly resembles an eagle's talon and hence the name^[14]. It can also present as conical, pyramidal or teat-like in appearance^[15,16,17].

The prevalence of Talon's cusp varies considerably among populations, ranging from 0.06% to 7.7%^[18,19]. The permanent dentition is more affected than the primary dentition, and the anomaly is more common in males than in females^[7]. Almost 92% of the affected (taloned) teeth in the permanent dentition have been found in the maxilla, with the lateral incisors being the most frequently involved (55%) followed by the central incisors (36%) and the canines^[7]. The presence of talons cusp on mandibular anterior teeth is extremely rare^[11].

The etiology of Talon's cusp is not well understood, but appears to have both genetic and environmental components. The Talon's cusp can occur as an isolated finding or in association with other dental anomalies such as peg-shaped lateral incisor, mesiodens, agenesis or impacted canines, complex odontomes, megadont, dens evaginatus of posterior teeth, shovel-shaped incisors, dens invaginatus and exaggerated Carabelli cusp or rarely germination as presented in our case^[11]. The Talon's cusp appears to be more prevalent in patients with Rubinstein-Taybi syndrome, Sturge-Weber syndrome, Mohr syndrome, incontinentia pigmenti achromians and Ellis-van Creveld syndrome^[11].

Radiographically it appears as a V shaped structure superimposed over the normal image of tooth and is inverted in mandibular teeth. Similar finding was observed in our case. Small talon (semi talon) cusps are usually asymptomatic and need no treatment. Large talon (trace talon) cusps may cause clinical problems including displacement of the affected tooth, occlusal interference, irritation of the tongue during speech and mastication, carious lesion in the developmental grooves, pulpal necrosis, periapical pathosis, attrition of the opposing tooth and periodontal problems due to excessive occlusal forces^[20].

No such complaints were noted in our case and hence long term follow up was considered. The treatment options for Talon's cusp involve careful clinical judgement and based on radiological examination requires removal of cusp and endodontic consideration, selective grinding, extraction and replacement with either fixed or partial denture^[7].

Conclusion

Geminated taloned teeth are a rare and unusual occurrence especially when it occurs in the mandibular anterior region. They pose a number of clinical and aesthetic problems and care should be taken to identify these developmental anomalies and treat accordingly to reduce discomfort to the patient.

References:

- 1) Rao B D, Hegde S. A Talon Cusp on Fused Teeth Associated with Hypodontia: Report of a Unique Case. *Eur J Dent*. 2010 January; 4(1): 75–80. [PubMed]
- 2) Brook AH, Winter GB. Double teeth. A retrospective study of 'geminated' and 'fused' teeth in children. *Br Dent J*. 1970;129:123–130. [PubMed]
- 3) Chaudhry SI, Sprawson NJ, Howe L, Nairn RI. Dental twinning. *Br Dent J*. 1997;182:185–188. [PubMed]
- 4) Yuen SW, Chan JC, Wei SH. Double primary teeth and their relationship with the permanent successors: a radiographic study of 376 cases. *Pediatr Dent* 1987;9:42–48.
- 5) Prabhakar AR, Kaur T, Nadig B. Bilateral fusion of permanent mandibular incisors with Talon's cusp: A rare case report. *J Oral Maxillofac Pathol* 2009;13:93–6.
- 6) Kelly JR. Gemination, Fusion, or Both? *Oral Surg* 1978;45:655–6.
- 7) Hattab FN, Hazza'a AM. An Unusual Case of Talon Cusp on Geminated Tooth. *J Can Dent Assoc* 2001; 67:263–6
- 8) Spouge JD. *Oral pathology*. St. Louis: C.V. Mosby Co.; 1973.
- 9) Gondoz k, Anikguz A. An unusual case of Talon cusp on a geminated tooth. *Braz Dent J* 2006;17:343–6.
- 10) Karjodkar FR, Gupta A. Mandibular Talon cusp: a case report. *Oral Surg Oral Med Oral Pathol Oral Radiol Endod* 2007;103:e86–7.
- 11) Ramalingam K, Gajula P. Mandibular talon cusp: A rare presentation with the literature review. *J Nat Sci Biol Med*. 2011 Jul-Dec; 2(2): 225–228. [PubMed]
- 12) Shankar AA, Koshy AV, Duggal DS, Dandekar RC. Synodontia with talon cusp: A case report and review of literature. *OMPJ*. 2011;2:165–9.
- 13) Rao PK, Mascarenhas R, Jodalli P, Kumar V, Devadiga D. Fusion and Gemination in a Primary Mandibular Anterior teeth: A Case Report. *Cukurova Medical Journal* 2014;39(2): 336–338.
- 14) Mellor JK, Ripa LW. Talon cusp: a clinically significant anomaly. *Oral Surg Oral Med Oral Pathol* 1970; 29(2):225–8.
- 15) Mader CL. Talon cusp. *J Am Dent Assoc* 1981; 103(2):244–6.
- 16) Davis PJ, Brook AH. The presentation of talon cusp: diagnosis, clinical features, associations and possible etiology. *Br Dent J* 1986; 160(3):84–8.
- 17) Hattab FN, Yassin OM, al-Nimri KS. Talon cusp — clinical significance and management: case reports. *Quintessence Int* 1995; 26(2): 115–20. [PubMed]
- 18) Sedano HO, Carreon Freyre I, Garza de la Garza ML, Gomar Franco CM, Grimaldo Hernandez C, Hernandez Montoya ME, and others. Clinical orodental abnormalities in Mexican children. *Oral Surg Oral Med Oral Pathol* 1989; 68(3):300–11. [PubMed]
- 19) Chawla HS, Tewari A, Gopalakrishnan NS. Talon cusp — a prevalence study. *J Indian Soc Pedod Prev Dent* 1983; 1(1):28–34.
- 20) Hattab FN, Yassin OM, al-Nimri KS. Talon cusp in permanent dentition associated with other dental anomalies: review of literature and report of seven cases. *J Dent Child* 1996; 63(5):368–76. [PubMed]