

A Hepatic Outflow Obstruction (Budd-Chiari Syndrome) Case Due to Multiple Hypercoagulable Status

Yusuf Yazgan (*), Kemal Oncu (*), Mustafa Kaplan (*), Alpaslan Tanoglu (*), İrfan Küçük (*),
Halil Onur Ozari (*), Levent Demirturk (*), Murat Velioglu (**)

SUMMARY

We present here a case of a 22-year-old male patient with Budd-Chiari syndrome owing to alliance of multiple hypercoagulable conditions. The patient was admitted to our hospital for assesment of hepatosplenomegaly and ascites. By doppler ultrasonography, computed tomography and vena cavagraphy, Budd-Chiari syndrome was diagnosed. Results of diagnostic tests exhibited decreased activity, decreased antigenic concentration of Antithrombin, low protein C activity, heterozygote Factor V Leiden mutation. In clinical progress, acute severe hepatic failure with encephalopathy occured and the patient was transferred to an another medical center for liver transplantation.

Key words: *Budd-Chiari Syndrome, Antithrombin deficiency, low protein C activity, Factor V Leiden mutation, acute hepatic failure*

ÖZET

Birden Çok Nedene Bağlı Bir Budd-Chiari Sendromu Vakası Birkaç koagülasyon yapıcı nedene bağlı Budd-Chiari

Sendromu gelişmiş 22 yaşında bir erkek olguyu sunuyoruz. Olgu hastanemize hepatosplenomegali ve asit etyolojisinin belirlenmesi için yönlendirilmiş bir vaka idi. Klinik değerlendirme ve yapılan doppler ultrasonografi, bilgisayarlı tomografi ve vena cavagrafi sonrası Budd-Chiari sendromu tanısı kondu. Etiyolojiye yönelik yapılan kan tetkiklerinde; antitrombinin azalmış aktivitesi ve azalmış antijenik konsantrasyonu, düşük protein C aktivitesi, heterozigot Faktör V Leiden mutasyonu tespit edildi. Klinik seyrinde vakada akut hepatik yetmezlik ve ciddi ensefalopati tablosu gelişti. Hasta başka bir merkeze karaciğer transplantasyonu için yönlendirildi.

Anahtar kelimeler: *Budd-Chiari Sendromu, Antitrombin eksikliği, düşük protein C aktivitesi, Faktör V Leiden mutasyonu, akut hepatik yetmezlik*

Introduction:

Primary Budd-Chiari syndrome (BCS) is a rare disorder caused by thrombosis of the hepatic veins or the terminal portion of the inferior vena cava. Its estimated incidence ranges from 0.2 to 0.8 per million per year (1). In developed countries, the hepatic vein thrombosis is the most frequent presentation, however in developing countries membranous blockade is the most common cause of the BCS. BCS is closely associated with prothrombotic conditions especially with hematologic disorders. For example primary myeloproliferative diseases (i.e. polycythemia vera) may account for nearly half of the all cases (2). Tumors, pregnancy, infections are also other common reasons. Oral contraceptives raise the risk of BCS by nearly two-fold (3). Other BCS related hypercoagulable conditions are antiphospholipid syndrome, paroxysmal nocturnal hemoglobinuria, and lack of antithrombin, protein C and S, Factor V Leiden mutation.

Factor V Leiden (Active Protein C (APC) resistance) is the most frequent cause of inherited thrombophilia, accounting for nearly half of all cases. This fact is related to the crucial position of factor V Leiden in both the coagulation and anticoagulation pathways. Antithrombin (AT) deficiency which is an autosomal dominant inherited disease, is also strongly related with venous thrombosis. Decreased AT values, which even slightly below the normal range, increase the risk of thrombosis. AT deficiency is closely related with cerebral, pulmonary, portal and mesenteric venous thrombosis (4). The phenotype of patients with heterozygous protein C deficiency is extremely comparable to hereditary antithrombin deficiency. The thrombotic risk due to protein C deficiency and other inherited thrombophilias has been assessed in two ways: evaluation of patients with deep vein thrombosis and evaluation of families with thrombophilia. In literature, co-existence of multiple hypercoagulable status related BCS cases are very rare (5). We present here a young male patient with acute hepatic failure and BCS due to congenital AT deficiency, low protein C activity, and heterozygote Factor V Leiden mutation.

Case Report:

In July 2010, a 22 year-old male patient was referred from another hospital to our service for assesment of ascites and hepatosplenomegaly. He was complaining of epigastralgia, abdominal dullness, nausea and fatigue over the past 4 weeks. His past medical history was very interesting. In July 2009, he admitted to a hospital for suffering left hipalgia and walking difficulty. He was diagnosed as septic arthritis, brucellosis and he was performed arthroscopic debridement and given brucella treatment. After 2 months he reoperated for the same problem in the same hospital. After being discharged from that

*GATA Haydarpasa Training Hospital, Gastroenterology Department. 34668 Uskudar Istanbul, Turkey

**GATA Haydarpasa Training Hospital, Radiology Department. 34668 Uskudar Istanbul, Turkey

Ayrı basım isteği: Mustafa Kaplan
GATA Haydarpasa Training Hospital,
Gastroenterology Department.
34668 USKUDAR-ISTANBUL, TURKEY
Phone: 90 216 5422020-3505
e-mail: dr_mustafakaplan@yahoo.com

Date submitted: Dec 29, 2011 • Data accepted: Mar 08, 2012 • Online publication date: June 20, 2014

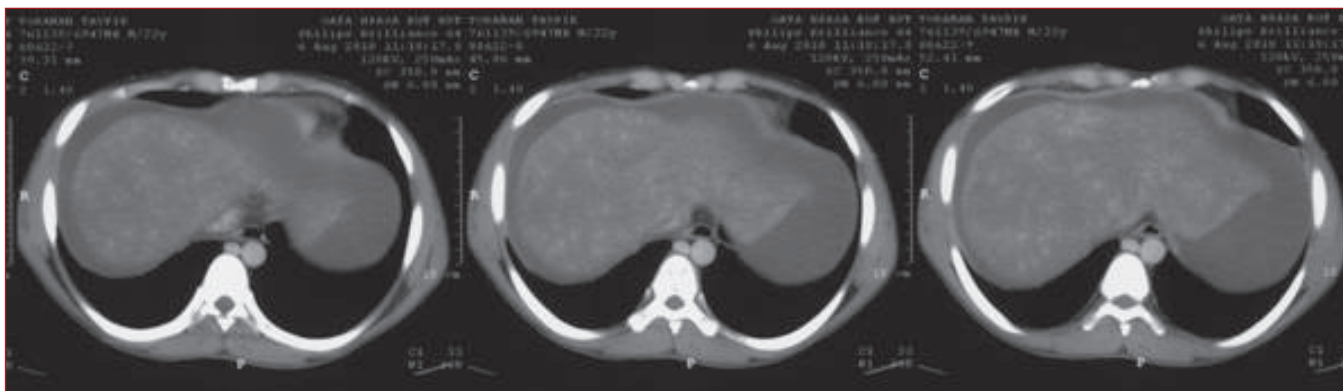


Figure 1. Computed tomography imaging: Showing big, heterogen and edematous liver, obstruction in hepatic veins and massive ascites

hospital, in the control examination, laboratory examinations revealed elevated erythrocyte sedimentation rate, high C reactive protein (CRP) level and pleural effusion. Owing to these laboratory findings and dyspnea he was referred to Pulmonary Medicine Service, in January 2010. In that service, he was diagnosed as pulmonary thromboembolism and warfarin was given. At that time the cause of the thromboembolism was not examined. He gave up taking warfarin without awareness of his doctors. Four months later, the patient presented to a provincial hospital complaining of abdominal dullness and fatigue. In that hospital, hepatosplenomegaly and ascites was diagnosed and he was referred to our service. Socially, he was a bachelor. He had no history of previous alcohol drinking or smoking. He was sexually inactive. Family history was negative.

On physical examination, the vital signs showed a temperature of 36 C, heart rate of 74 beats/min, and a respiratory rate of 16/minute, a blood pressure of 110/70 mmHg, and an oxygen saturation of 97% on room air. His height was 1.62 cm, and weight was 54 kg. He was looking older than his stated age and he was malnourished. Pulmonary auscultation displayed decreased lung sounds at the lower

part of the lungs and cardiovascular examination showed no pathology. Abdominal examination revealed mild hepatosplenomegaly and ascites. There was an operation scar on the right hip. Spider angioma, palmar erythema and pretibial edema were all absent.

Laboratory data showed a normal white cell count. The hemoglobin was 11.1 g/dL and hematocrit was 34,2%, platelets was $283 \times 103/\text{mL}$. A comprehensive routine blood count panel was as follows: Albumin 3.2 g/dl, alanine aminotransferase 28 IU/l, aspartate aminotransferase 40 IU/l, total bilirubin 1.4 mg/dl, gamma-glutamyltransferase 44 IU/l, prothrombin time 16.9 seconds, creatinine 1.22 mg/dl, ceruloplasmin 405 IU/l, serum copper 136 mcg/ml, parathormone 143 pg/ml, cyanocobalamine 629 pg/ml, C-reactive protein (CRP) 25 mg/dl (normal range, 0-8), Rose Bengal-Negative, Hepatitis A, B, and C antibodies were all negative, HIV was non-reactive, Cold agglutinin test-Negative, Venereal Disease Research Laboratory (VDRL)-Negative, antineutrophil cytoplasm antibodies (c-ANCA), antineutrophil perinuclear antibodies (p-ANCA), antinuclear antibodies (ANA) and anticardiolipin antibodies (ACA IgM, IgG) were all negative, but antismooth muscle antibodies (ASMA) were positive, antiphospholipid

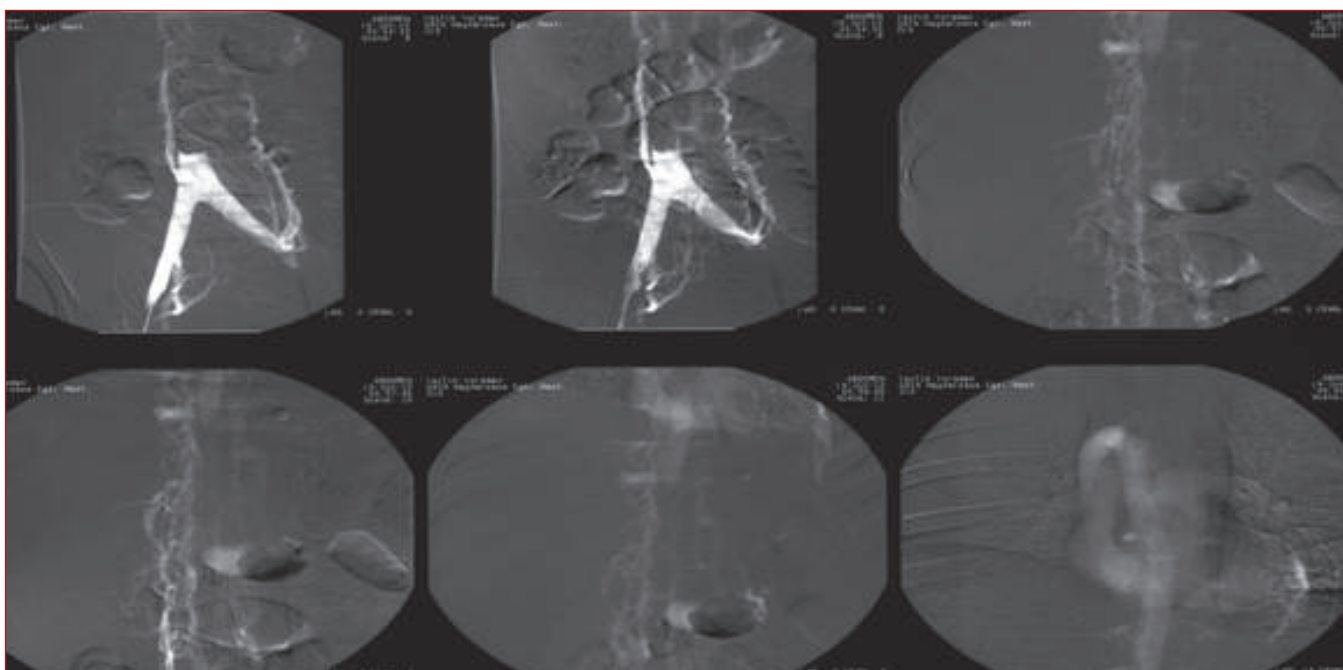


Figure 2. Vena Cavagraphy demonstrating total occlusion of inferior vena cava and lower extremity venous drainage was flowing directly to superior vena cava via paravertebral collaterals and hemiazygous vein

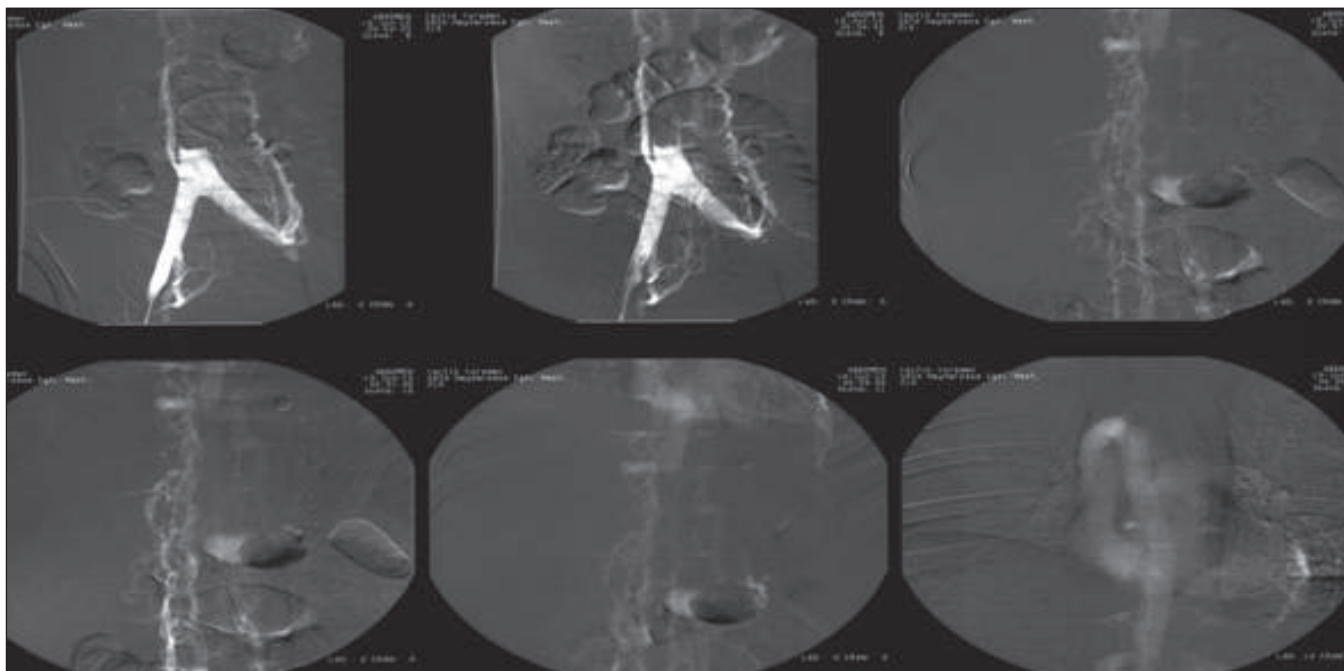


Figure 3. The venous phase of selective superior mesenteric arterial angiography demonstrating extrahepatic collateral veins and low density filling of portal vein

antibodies-Negative, homocysteine 13.69 $\mu\text{mol/l}$ (normal range, 6-12), antithrombin antigen concentration 15.5 mg/dl (normal range, 19-31), AT activity 38.4% (normal range, 83-110), protein C activity 60.4% (normal range, 70-140), protein S activity 71.5% (normal range, 58-128), factor V Leiden mutation analyse- Heterozygote mutant, MTHFR C677T mutation analyse- Homozygote mutant. Abdominal paracentesis performed and serum-ascites albumin gradient was <1.1 . Malignancy examination of ascites was negative.

Ultrasonography of the abdomen demonstrated hepatosplenomegaly. Computed tomography of the abdomen revealed hepatosplenomegaly, suspected thrombus formation in the vena cava inferior at the suprarenal and infrarenal levels, heterogeneity of liver parenchyma, massive ascites and prediagnosis of Budd-Chiari Syndrome (Fig.1). In doppler ultrasonography of the liver, there was a very slow flow in the hepatic veins with perihepatic venous collaterals. Upper gastrointestinal system endoscopy revealed Grade I-II esophagus varices. Inferior/superior vena cavography showed total occlusion of inferior vena cava and lower extremity venous drainage was flowing directly to superior vena cava via paravertebral collaterals and hemiazygous vein (Fig.2). The venous phase of selective superior mesenteric arterial angiography demonstrated extrahepatic collateral veins and low density filling of portal vein (Fig. 3).

As a result of all physical examinations, clinical picture, laboratory and imaginary findings Budd-Chiari Syndrome was diagnosed. Liver biopsy was not performed because the patient denied it. The patient consulted to cardiovascular surgeons for thrombectomy. After the comment of unclearable thrombus, we began low molecule weight heparin therapy. Unfortunately acute hepatitis and hepatic encephalopathy occurred. Due to his family's request he referred to another hospital for liver transplantation.

Discussion

The Budd-Chiari syndrome (BCS) is an uncommon but

clinically important disorder which was defined as obstruction of hepatic venous outflow anywhere from the small hepatic veins to the suprahepatic inferior vena cava (1). In the developed countries, thrombosis is the most common cause of BCS. Complications caused by portal hypertension and deterioration of liver function are the main features of this syndrome.

In previous studies, factor V Leiden mutation was detected in nearly 20% of cases with BCS. BCS occurs easily in those particular patients who have additional risk factors like pregnancy, using oral contraceptives etc. (6). Factor V Leiden is the most frequent reason of inherited thrombophilia, accounting for nearly 50% of all cases. Factor V is an inactive cofactor which is activated by thrombin. This activation reaction results as factor Va formation, which then acts as a cofactor in the activation of prothrombin to thrombin. The factor V Leiden mutation conduces to a hypercoagulable condition for two reasons, increased coagulation and decreased anticoagulation. Genetic and acquired conditions are the two main causes for APC resistance. Heterozygosity for the factor V Leiden mutation accounts for nearly 90-95 percent of cases of the APC resistance phenotype. A very smaller number of homozygotes exist. Acquired conditions include elevated factor VIII levels, use of oral contraceptives, pregnancy, the existence of antiphospholipid antibodies and some of unknown causes (7).

Antithrombin, also known as heparin cofactor I, is a vitamin K-independent glycoprotein, a physiological inhibitor of serin-proteases (Xa, IXa), and most important inhibitor of thrombin. Deficiency of AT is a well described risk factor for thrombophilia and the gene for AT has been localized at chromosome 1. There are acquired and hereditary forms of AT deficiency. Hereditary AT deficiency which is usually autosomal dominant was the first recognised reason of thrombophilia (8). Acquired deficiency has been documented in pregnancy, oral contraceptives usage and after surgery or trauma (9). The most common presentation sites of thrombophilia are the deep

veins of the leg and the iliofemoral veins and the mesenteric veins (10). Uncommonly involved sites include the vena cava and the renal veins, retinal, cerebral, or hepatic veins (Budd-Chiari syndrome).

Protein C is a vitamin K-related protein and it is synthesized in the liver. The gene for protein C is localized at chromosome 2 and is closely related to the gene for factor IX (11). There are two subtypes of protein C deficiency (12). The type I deficiency is the more common type in which plasma protein C concentrations are usually decreased (13). Patients with the type II deficiency have normal plasma protein C antigen levels with decreased functional activity. There are three clinical syndromes associated with protein C deficiency: Venous thromboembolism, neonatal purpura fulminans and warfarin-induced skin necrosis. In the previous studies, congenital protein C deficiency was detected in approximately 2 to 5 percent of cases presenting with thromboembolism (14).

In our patient, both decreased functional activity and antigen concentration of AT was determined and also protein C deficiency and heterozygote Factor V Leiden mutation were diagnosed for the causes of Budd-Chiari Syndrome. The findings of abdominal and doppler ultrasonography, upper GIS endoscopy, CT, MR and angiography-cavagraphy suggested and diagnosed Budd-Chiari Syndrom. It is a very rare encountered BCS case underlying three different causes. Deficiencies in protein S, C and AT have been informed as factors for BCS. However, in the view of normal physical examination, normal liver and kidney functions, heterozygote Factor V Leiden mutation and previously pulmonary thromboembolism history, multiple congenital hypercoagulable status accused for the current BCS event.

There have been four previously reported therapeutic options for BCS: medical treatment, surgical decompression, TIPSS placement/stent insertion into the hepatic veins, and liver transplantation (15). However, none of these options alone is the gold standart for the therapy, but their combination may provide long-term survival. As a matter of fact, it is very crucial to treat the problem underlying the thrombosis and it is very critical to prevent progression of thrombosis. In our patient we prescribed low molecule weight heparin and planned to continue with warfarin therapy. Unfortunately our patient got worse, acute liver failure with severe encephalopatya occurred and we referred him to another hospital for liver transplantation.

In conclusion, we have reported a very rare coexistence of multiple hypercoagulable situations (decreased activity, decreased antigenic concentration of AT, low protein C activity, heterozygote Factor V Leiden mutation) which caused Budd-Chiari Syndrome. BCS is a rare but crucial situation and thrombophilia is the underlying factor. A complete search for thrombophilia is very critical and should not be stopped after identification of a sole cause, because patients may have more than one underlying disorder as our patient.

References

1. Plessier A, Rautou PE, Valla DC, Management of hepatic vascular diseases, *Journal of Hepatology*, 2012, 25-38.
2. Valla DC: Hepatic vein thrombosis (Budd-Chiari syndrome) *Semin Liver Dis.* 2002;22:5.
3. Denninger MH, Chait Y, Casadevall N, et al: Cause of portal or hepatic venous thrombosis in adults: The role of multiple concurrent factors. *Hepatology.* 2000;31:587.
4. Sakuragawa N, Takahashi K, Kondo S, Koide T. Antithrombin III Toyama: a hereditary abnormal antithrombin III of a patient with recurrent thrombophlebitis. *Thromb Res* 1983;31:305-17.
5. Das M, Carroll SF. Antithrombin III deficiency: an etiology of Budd-Chiari syndrome. *Surgery* 1985;91:242-5.
6. Deltenre P, Denninger MH, Hillaire SM, Guillin MC, Casadevall N, Briere J, Erlinger S, Valla DC: Factor V Leiden mutation related to Budd-Chiari syndrome. *Gut.* 2001;48:264-268.
7. Zöller, B, Svensson, PJ, He, X, et al. Identification of the same factor V gene mutation in 47 out of 50 thrombosis-prone families with inherited resistance to activated protein C. *J Clin Invest* 1994; 94:2521.
8. Zhou, A, Huntington, JA, Carrell, RW. Formation of the antithrombin heterodimer In vivo and the onset of thrombosis. *Blood* 1999; 94:3388.
9. Bick RL. Clinical relevance of antithrombin III. *Semin Thromb Haemost* 1982;8:276-87.
10. Wilson, C, Walker, ID, Davidson, JF, et al. Mesenteric venous thrombosis and antithrombin III deficiency. *J Clin Pathol* 1987; 40:906.
11. Foster, DC, Yoshitake, S, Davie, EW. The nucleotide sequence of the gene for human protein C. *Proc Natl Acad Sci U S A* 1985; 82:4673.
12. Reitsma, PH. Protein C deficiency: From gene defects to disease. *Thromb Haemost* 1997; 78:344.
13. Broekmans, AW, Bertina, RM. Protein C. In: *Recent Advances in Blood Coagulation*, volume four, Poller, L (Ed), Churchill Livingstone, New York 1985. p.117.
14. Gladson, CL, Scharrer, I, Hach, V, et al. The frequency of type I heterozygous protein S and protein C deficiency in 141 unrelated young patients with venous thrombosis. *Thromb Haemost* 1988; 59:18.
15. Ringe B, Lang H, Oldhafer KJ, Gebel M, Flemming P, Georgii A, et al. Which is the best surgery for Budd-Chiari syndrome: venous decompression or liver transplantation? A single center experience with 50 patients. *Hepatology* 1995;21:1337-44.