

Delayed diagnosis and sequela of infantile septic hip dislocation as a complication of chicken pox: a case report

Özcan Pehlivan (*), Selami Süleymanoğlu (**), Feridun Çilli (*), Selami Çakmak (*)

SUMMARY

Soft tissue infection and subsequent septic arthritis of the hip developing after chicken pox in a 8-month-old male infant are presented in this case report. The diagnosis of septic hip infection was diagnosed lately after the findings of infection resolved and it caused dislocation of the hip. Functional outcome was satisfactory in the patient with the sequela of Choi type IIA in the follow-up after one year of surgical intervention.

Key words: *Chicken pox, dislocation, hip, septic arthritis*

ÖZET

Su çiçeğinin komplikasyonu olarak geç tanı konmuş ve sekel bırakmış infantil septik kalça dislokasyonu: bir olgu sunumu

Bu olgu sunumunda 8 aylık erkek bebekte su çiçeği enfeksiyonu sonrası gelişen yumuşak doku enfeksiyonu ve takiben oluşan kalça septik artriti rapor edilmiştir. Septik kalça enfeksiyonu tanısı, enfeksiyon bulguları azaldıktan ve kalçada dislokasyona sebep olduktan sonra geç olarak konmuştur. Cerrahi müdahale sonrası, birinci yıl sonu takibinde Choi tip IIA kalça sekeli olan hastada fonksiyonel sonuçlar tatmin edici bulunmuştur.

Anahtar kelimeler: *Su çiçeği, dislokasyon, kalça, septik artrit*

Introduction

Proper surgical and pharmacologic treatment of acute childhood septic arthritis of the hip is required to minimize the risk and severity of the late term sequelae that vary from no residual deformity to complete loss of femoral head and neck (1-5). Factors that are directly correlated with the increased severity of the late term sequelae are younger age, staphylococcal infection, delayed treatment, and inadequacy of surgical and pharmacologic treatment (2,3,5,6). In this paper we present the short term results of delayed diagnosis of infantile septic arthritis of the hip as a complication of chicken pox progressing to dislocation.

Case Report

A 8-month-old male infant was admitted to the department of pediatrics with the complaints of fever and vesicular skin lesions diagnosed as chicken pox, and serum varicella IgM antibody level confirmed the diagnosis. Symptomatic treatment was prescribed. Three days after the initial presentation the child was readmitted to the department of pediatrics with the erythema extending from right upper thigh to the knee, severe irritation with the right hip movements, and higher fever than initial presentation. Initial findings showed a rectal temperature of 39.5 °C, white blood cell count of 36.000/mm³, C-reactive protein level of 117 mg/L and erythrocyte sedimentation rate of 78 mm/h. All were supporting a bacterial infection. The child was admitted to the clinic with the diagnosis of cellulites, and intravenous ceftriaxone and clindamycine treatment was initiated. As the signs and symptoms regressed, the child was discharged with oral antibiotic prescription five days after the admission to the hospital. With the only complaint of asymmetrical lower limbs, the child was referred to the department of orthopedics 25 days after the second presentation to the department of pediatrics. On physical examination right lower limb was slightly shorter and right hip abduc-

* Department of Orthopedics, Haydarpaşa Education Hospital, Gulhane Military Medical Faculty

** Department of Pediatrics, Haydarpaşa Education Hospital, Gulhane Military Medical Faculty

Reprint request: Dr. Özcan Pehlivan, İlyas Bey Cad. No: 49/51, Yedikule-34310, İstanbul

E-mail: ozipeh@yahoo.com

Date submitted: November 21, 2007 • **Date accepted:** February 28, 2008

tion was slightly limited. There was no pain with the hip movements. After the detailed history of the child was obtained, laboratory tests were ordered in addition to roentgenograms of pelvis. Serum laboratory values demonstrated a white blood cell count of $10.800/\text{mm}^3$, C-reactive protein level of 5.2 mg/L , and erythrocyte sedimentation rate of 61 mm/h . Rontgenograms of the pelvis revealed right hip dislocation, destruction of the femoral neck, ischemic necrosis of the femoral head with decreased density and similar acetabular index angles (20°) on both sides (Figure 1). History, increased sedimentation rate and radiographic findings led us to suspect a missed diagnosis of septic arthritis of the right hip which progressed to hip dislocation with destruction of the proximal femur. Under general anesthesia open surgical drainage, irrigation and reduction of the hip were performed with anterior approach. During the surgical procedure before opening the hip joint capsule, the capsule was noted as distended and was aspirated before performing capsulotomy for the bacteriologic studies. Aspiration revealed a serous fluid with no sign of pus. After capsulotomy was performed evacuation of the fluid was done. A sample of synovial tissue was obtained for pathological evaluation. Femoral head was noted as irregular with intact soft cartilage covering it. After irrigation femoral head was reduced and capsulorraphy was performed. Following operation a one-and-one-half-hip spica cast was applied with the hip 100° of flexion, 45° of abduction, and neutral rotation. There was no growth on bacteriological culture of material, and pathological evaluation was reported as chronic nonspecific synovitis. Six weeks after the operation the cast was removed under general anesthesia and the physical and fluoroscopic examination of the hip was noted as stable and reduced hip joint. Femoral neck was deformed and femoral head was invisible (Figure 2). A

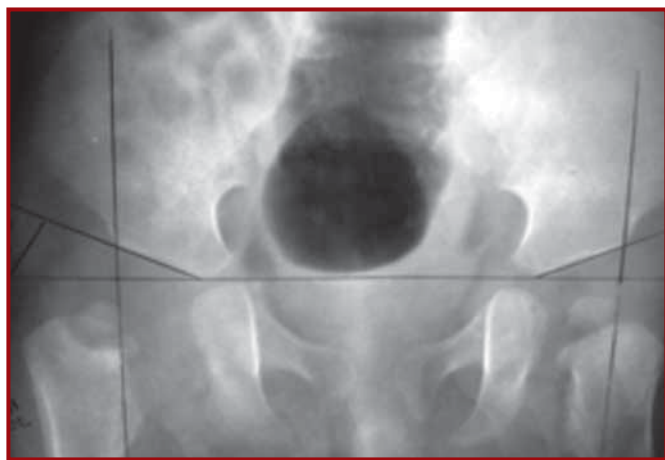


Figure 1. At the initial presentation to the department of orthopedics, radiograph of the pelvis demonstrates deformed proximal femoral metaphysis and small and low density dislocated femoral head on the right side, but similar acetabular development on both sides

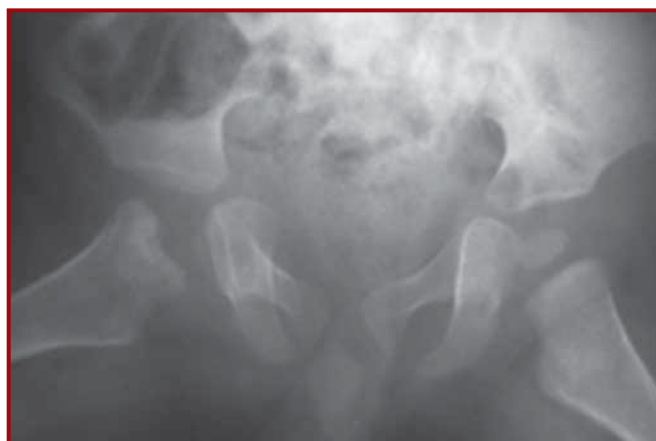

Figure 2. Six weeks after the operation, radiograph of the pelvis demonstrates deformed proximal femoral metaphysis and no visible femoral head on the right. Note the right hip is reduced

second cast with the hip 45° of flexion and abduction was applied with the knees out of the cast. The second cast was held for four weeks and then removed in the clinic. Radiographs of the pelvis showed a destruction of the femoral neck and a difficultly visible ossified small femoral head. Physical examination revealed a stable hip. We did not apply any kind of immobilization after this point and the child was called for routine controls. He began walking independently at the age of 12 months. The last control was made at the post-operative 12 month. Physical examination showed full range of motion of the affected hip with similar foot progression and thigh-foot angles on both sides. The child was active without any restriction of movements except for only slightly noticeable waddling during walking and running. Radiographs showed an ossified femoral head on a short femoral neck and mild acetabular dysplasia (Figure 3). Radiographic appearance made us to classify the condition as the Choi Type IIA hip septic arthritis sequela (2,3,7). At this point observation with follow-up visits was decided.

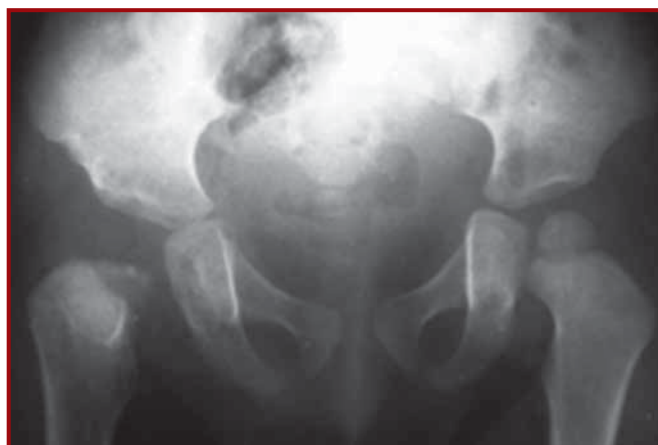

Figure 3. At the last follow-up visit 12 months after the operation, radiograph of the pelvis demonstrates a reduced, reossified and deformed femoral head, short but remodeled femoral neck, and mild acetabular dysplasia on the right side (Choi type IIA sequela)

Discussion

Acute septic arthritis of the hip is an orthopedic emergency requiring proper management to save the hip joint that otherwise deteriorates with time. The sequelae that might follow septic arthritis of the hip in an infant include premature closure of the triradiate cartilage and proximal femoral physis, osteonecrosis of the femoral head, chronic osteomyelitis, subluxation, dislocation, and varying degrees of proximal femoral destruction (2,3,5-8). The most important factors that determine the severity of the sequelae are the age of the child, virulence of the causative organism, time interval between the beginning of the septic event in the joint, and diagnosis and treatment (2,3,5,6).

Infecting organisms invade the hip joint by one of the two ways; directly via the hematogenous route or indirectly via the invasion from an adjacent focus. As the septic process begins, destroying cascade begins eventually. In addition to the direct toxic effects of the inflammatory response and bacterial toxins on the cartilage, increased intracapsular pressure further deteriorates the condition leading to subluxation, dislocation and ischemic necrosis of the femoral head (2,5). As the diagnosis and appropriate treatment delay, the destructive effect of the septic process increases whatever the age of the patient or the infecting organism is. This critical period is the first 4 days after the beginning of the septic event if the goal is to have a functional and the least destroyed hip joint (2,5,6).

Suspicion is the first stage for the diagnosis. Although the sign and symptoms in the early childhood might be obscured, in general history of a recent infection or conditions that depress the immune system, irritation with hip movements, limping, fever ($>39^{\circ}\text{C}$), high erythrocyte sedimentation rate ($>40\text{ mm/h}$), high serum white blood cell count ($>12.000/\text{mm}^3$) and high C-reactive protein level ($>20\text{ mg/L}$) all should force the physician to suspect for the septic arthritis of the hip (5,8).

In our presented case the most probable scenario developed as follows; immune status was depressed by the varicella virus infection caused the bacteria, particularly the group A- β hemolytic Streptococci, to invade through the epidermis where the varicella vesicles were located on the thigh (9). Then they spreaded to the hip joint directly or indirectly. The clinical picture was defined as the fasciitis of the thigh although the clinical and laboratory findings supported an additional pathological condition that had to be suspected as septic arthritis of the hip. As the septic arthritis of the hip was missed, every stage of the destroying cascade of the septic event took place and progressed with the end result of a dislocated and destroyed hip joint. As the diagnosis of missed septic arthritis of the

hip was made, acute septic event was resolved and the dislocated and deformed femoral head were reduced by open surgical intervention and immobilized in a cast until the reossified femoral head was visible on plain radiographs as proposed by Choi et al. (2).

The presented case in this paper has a short follow-up period of one year. According to the criteria that were described by Hunka et al. (4), the functional result at this point was considered satisfactory with pain free full range of motion without any restriction of activities. Late sequelae of the septic arthritis of hip can be described according to the radiographic appearance at the last follow-up visit or at skeletal maturity (2,3,7). The last radiographic evaluation of the presented case gave us the impression as Choi type IIA sequela where the epiphysis, physis and metaphysis are all involved with a resulting coxa breva and a deformed head (2,3,7). According to the algorithmic treatment protocol of Choi et al. (3), we decided to continue observation and follow-up at this point.

Although the final result is, at least functionally, satisfactory at this point, the future progression does not seem so bright and some other operations may be required in the future as the child develops. The fate of the hip would be changed dramatically with the proper treatment if the suspicion for the septic arthritis of the hip would be on time within 4 days after the onset of the septic event in the hip joint.

References

1. Caksen H, Ozturk MK, Uzum K, Yuksel S, Ustunbas HB, Per H. Septic arthritis in childhood. *Pediatr Int* 2000; 42: 534-540.
2. Choi IH, Pizzutillo PD, Bowen JR, Dragann R, Malhis T. Sequelae and reconstruction after septic arthritis of the hip in infants. *J Bone Joint Surg Am* 1990; 72: 1150-1165.
3. Choi IH, Yoo WJ, Cho TJ, Chung CY. Operative reconstruction for septic arthritis of the hip. *Orthop Clin North Am* 2006; 37: 173-183.
4. Hunka L, Said SE, MacKenzie DA, Rogala EJ, Cruess RL. Classification and surgical management of the severe sequelae of septic hips in children. *Clin Orthop Relat Res* 1982; 171: 30-36.
5. Sucato DJ, Schwend RM, Gillespie R. Septic arthritis of the hip in children. *J Am Acad Orthop Surg* 1997; 5: 249-260.
6. Bennett OM, Namnyak SS. Acute septic arthritis of the hip joint in infancy and childhood. *Clin Orthop Relat Res* 1992; 281: 123-132.
7. Choi IH, Shin YW, Chung CY, Cho TJ, Yoo WJ, Lee DY. Surgical treatment of the severe sequelae of infantile septic arthritis of the hip. *Clin Orthop Relat Res* 2005; 434: 102-109.
8. Caird MS, Flynn JM, Leung YL, Millman JE, D'Italia JG, Dormans JP. Factors distinguishing septic arthritis from transient synovitis of the hip in children. A prospective study. *J Bone Joint Surg Am* 2006; 88: 1251-1257.
9. Poon AH, Terk MR, Colletti PM. The association of primary varicella infection and streptococcal infection of the cutaneous and musculoskeletal system. A case report. *Magn Reson Imaging* 1997; 15: 131-133.