

# Proanthocyanidine alleviates lung damage induced by nitrogen mustard

Orhan Yücel (\*), Onur Genç (\*), Önder Öngürü (\*\*), Ahmet Aydın (\*\*\*), Mehmet Ali Şahin (\*\*\*\*), Adem Güler (\*\*\*\*), Turan Karayılanoglu (\*\*\*\*), Ahmet Sayal (\*\*\*), Mehmet Dakak (\*)

## SUMMARY

Destructive properties of nitrogen mustard especially on respiratory system make it an effective chemical weapon with lack of an antidote. The aim of this study was to investigate the role of oxidative stress in mustard toxicity and the protective effect of proanthocyanidine. Rats were separated into three groups each containing fifteen rats. The three groups were control group which were exposed to none, nitrogen mustard group administered nitrogen mustard, and the last group administered nitrogen mustard and fed with proanthocyanidine containing diet (nitrogen mustard plus proanthocyanidine group). We demonstrated the harmful effects of nitrogen mustard over oxidative stress, and the therapeutic effects of proanthocyanidine by both histopathologically and biochemically using the oxidative stress parameters such as malondialdehyde, superoxide dismutase, catalase and glutathione peroxidase. Significant histopathologic lung lesions such as alveolar edema and alveolar congestion were observed in the nitrogen mustard group. Those lesions were less severe in the nitrogen mustard plus proanthocyanidine group. Proanthocyanidine treatment decreased malondialdehyde levels, which were initially elevated by nitrogen mustard administration, while superoxide dismutase, catalase and glutathione peroxidase activities remained similar to those of the nitrogen mustard only group. Our results revealed that oxidative stress has played a major role in mustard toxicity, and proanthocyanidine has had a substantial role in decreasing the toxic outcomes.

**Key words:** *Glutathione peroxidase, lung damage, malondialdehyde, nitrogen mustard, proanthocyanidine*

## ÖZET

### Proantosiyanidin nitrojen mustarda bağlı akciğer hasarını azaltır

Antidotu bulunmayan nitrojen mustard gazının özellikle solunum sistemi üzerinde görülen yıkıcı etkisi onu etkili bir kimyasal silah yapmaktadır. Bu çalışmanın amacı mustard toksisitesinde oksidatif stresin rolünün ve proantosiyanidin koruyucu etkisinin araştırılmasıdır. Ratlar her biri on beş hayvan içeren üç gruba ayrıldı. Bu üç grup hiç bir şeye maruz bırakılmamış kontrol grubu, nitrojen mustard uygulanan grup ve nitrojen mustard uygulanmış ve proantosiyanidin içeren diyetle beslenmiş gruplardı. Nitrojen mustardın oksidatif stres üzerinden zararlı etkileri ve proantosiyanidin terapötik etkileri hem histopatolojik hem de biyokimyasal olarak malondialdehid, süperoksid dismutaz, katalaz ve glutatyon peroksidaz gibi oksidatif stres parametreleri kullanılarak gösterildi. Nitrojen mustard grubunda alveolar ödem ve alveolar konjesyon gibi anlamlı histopatolojik akciğer lezyonları gözlemlendi. Bu lezyonlar nitrojen mustard uygulanmış ve proantosiyanidin içeren diyetle beslenmiş grupta daha az şiddette gözlemlendi. Proantosiyanidin tedavisi nitrojen mustard uygulamasıyla başlangıçta yükselmiş olan malondialdehid seviyelerini düşürürken, süperoksid dismutaz, katalaz ve glutatyon peroksidaz aktiviteleri nitrojen mustard grubuyla aynı seviyede kaldı. Sonuçlarımız mustard toksisitesinde oksidatif stresin önemli rol oynadığını ve proantosiyanidin toksik sonuçların azaltılmasında önemli bir etkiye sahip olduğunu göstermiştir.

**Anahtar sözcükler:** *Glutatyon peroksidaz, akciğer hasarı, malondialdehid, nitrojen mustard, proantosiyanidin*

## Introduction

One of the most important vesicant agents is mustard (1,2). It was first used in the battlefield during World War I by Germany (1,3). Sulfur mustard (SM) has posed a military threat and this is still considered as a major danger against humankind (3,4). Both SM and nitrogen mustard (NM) are known for their toxic effects (5). NM is a structural analogue of the SM (5). NM has become the prototypical cancer chemotherapeutic compound and has remained the standard compound for this purpose for many years (3,5). The most destructive properties of mustards are assumed to be upon respiratory system, eyes and skin (3,6,7). Mustard has many biological actions, but the cytotoxic mechanism of mustard has not been fully clarified (3-5). However, biological damage from mustard may result in DNA alkylation, cross linking of DNA, activation of proteases, resulting in proteolysis of several important enzymes and structural proteins, production of free radicals and induction of free radical mediated oxidative stress, inflammation, activation of TNF- $\alpha$ , part of the inflammatory cytokine (2,4,6-8). This leads to cellular death and inflammatory reaction (3,5,6). Mustard gas exposure also causes inflammatory lung diseases, including acute respiratory distress syndrome (6,7).

It is well known that proanthocyanidine (PC) is a free radical scavenger that has anti-inflammatory and anti-thrombotic effects (9,10). The grape seed PC extract contains 54% dimeric PCs, 13% trimeric PCs, 7% tetrameric PC, small amounts of monomeric, high-molecular-weight oligomeric PCs and flavonoids. Bagchi et al. have stated that grape seed extract containing PC provides superior antioxidant efficacy as compared to Vitamins C, E and  $\beta$ -carotene (11). Novel antioxidants may offer an effective and safe means of counteracting some of the problems and bolstering the (organism) body's defenses against free radicals and cardiovascular disease (11,12). Based on

\* Department of Thoracic Surgery, Gulhane Military Medical Faculty

\*\* Department of Pathology, Gulhane Military Medical Faculty

\*\*\* Department of Pharmaceutical Toxicology, Gulhane Military Medical Faculty

\*\*\*\* Department of Cardiovascular Surgery, Gulhane Military Medical Faculty

\*\*\*\*\* Department of Nuclear, Biologic and Chemical Warfare, Gulhane Military Medical Faculty

**Reprint request:** Dr. Orhan Yücel, Department of Thoracic Surgery, Gulhane Military Medical Faculty, Etilik-06018, Ankara, Turkey

**E-mail:** orhanycl@gmail.com

**Date submitted:** November 27, 2008 • **Date accepted:** December 21, 2008

this preventive effect in these experimental studies, we aimed to investigate the possible beneficial protective effects of PC in mustard toxicity.

NM is inexpensive, easily obtainable and frequently stockpiled. Because of those properties it has been used as a chemical warfare agent in conflicts and terrorist attacks. In recent years, a lot of experimental studies have been designed to investigate the cytotoxic mechanism induced by mustard and initial event leading to cell death. The aim of this study was to investigate the role of oxidative stress status in mustard toxicity and to determine the protective effect of PC which is a potent free radical scavenger in mustard toxicity.

### Material and Methods

**Animals:** The study was performed in the Animal Research Laboratory and was approved by the Ethics Committee. Forty five adult Ratus Norvegicus weighing between 140 and 160 g were used. The rats were separated into three groups by the "simple random sampling method" and each group contained fifteen rats.

**Chemicals:** NM and chemicals for oxidative stress related analysis were provided from Sigma–Aldrich Chemie GmbH (Taufkirchen, Germany) and organic solvents from Merck KGaA (Darmstadt, Germany). A commercially available PC was purchased from GNC Bakara A.S. (Proanthocyanidine: GN 6018, 100 mg, 90 capsules, Istanbul, Türkiye).

**Experimental design:** In experimental study, animals were divided into three groups. The first group was control group (CG) which was only exposed to vaporized 5 ml distilled water for 10 minutes. The second group was NM group (NMG) which was exposed to a toxic dose of vaporized 8 mg NM dissolved in 5 ml distilled water for 10 minutes (800 mg/m<sup>3</sup>/minutes). The third group was PC group (PCG) and PC containing diet (1X100+/-5 mg/kg rat body weight/day) was given orally by gavage to this group. PC intake in this group was started 8 h before being exposed to the same dose of NM as in the NMG and continued for three days. All exposures were performed in a 100 L volume chamber equipped with Chemical, Biological, Radiological, and Nuclear (CBRN) filters.

**The procedure:** Rats were anesthetized with intraperitoneal Ketamine hydrochloride (Ketamine hydrochloride solution in 5%, Parke – Davis licensed Eczacıbaşı Medical Industry, Istanbul) 90 mg/kg and Xylazine (Xylazine solution in 2%, by Parke – Davis licensed Eczacıbaşı Medical Industry, Istanbul, 10 mg/kg). Rats were placed in a chamber. All rats were heated (average temperature: 22±2 °C) by us-

ing tungsten electric bulb (100W/220V) and oxygen was supplied during the procedure. Rats were directly exposed to vaporized nitrogen mustard. Analgesia was obtained by using buterfenol (0.5 mg/kg, s.c.). In PCG, PC intake was started 8 h before NM application and continued 72 hour by gavage with a commercially available IH636 grape seed PC extract. In NMG, homogeneous methylcellulose solution intake was started 8 h before NM application and continued 72 h by gavage without a grape seed PC extract. Grape seed PC was homogenized in 2 mL 1% methylcellulose solution and then diluted with 0.9% NaCl to 10 mL (12). The rats were given 100±5 mg/kg of the grape seed PCs in the form of an extract (11). Thereafter, the animals were allowed to survive for an additional 72 hour. All rats were sacrificed after 72nd hour by giving lethal dose of xylazine and ketamine. Their chests were opened by median sternotomy. The lungs were removed and fixed in 10% buffered formalin solution immediately by intratracheal instillation for histopathological evaluation. One third of upper lobes of both lungs were kept in liquid nitrogen for oxidative stress status analysis before fixation.

**Tissue preparation for histopathological evaluation:** Both right and left lungs for all cases were evaluated for histopathological examination. After routine tissue processing, 4-µm thick sections from each formalin-fixed paraffin-embedded tissue were stained with haematoxylin and eosin (H&E). H&E stained slides were reviewed by two pathologists. Histological parameters including alveolar edema, alveolar congestion, alveolar hemorrhage, interstitial inflammation and bronchiolocentric inflammation were assessed semi-quantitatively using a 4-stage grading scale: negative (-), weakly positive (1+), moderately positive (2+), strongly positive (3+).

#### *Oxidative stress status related parameter analysis*

**Tissue preparation for oxidative stress status:** Tissue samples were homogenized in 0.2 mMol (pH 7.5) KCl buffer solution on ice using a glass homogenizer. Then homogenized samples were centrifuged for 10 min at 5000xg and 4 °C. Supernatant was used for the analysis (5,13-15).

**Glutathione peroxidase (GSH-Px) activity measurement:** GSH-Px activities in plasma samples and tissue homogenates were measured by the method described in our previous study (13). The reaction mixture was 50 mMol tris buffer, pH 7.6 containing 1 mMol of Na<sub>2</sub>EDTA, 2 mMol of reduced glutathione (GSH), 0.2 mMol of NADPH, 4 mMol of sodium azide and 1000 U of glutathione reductase (GR). Fifty µL of plasma or tissue homogenate and 950 µL



of reaction mixture were mixed and incubated for 5 min at 37 °C. Then the reaction was initiated with 10 µL of t-butyl hydroperoxide (8 mMol) and the decrease in NADPH absorbance was followed at 340 nm for 3 min. Enzyme activities were reported as u/mg in tissue.

**Malondialdehyde (MDA) level measurement:** MDA levels in plasma and tissue homogenate samples were determined in accordance with the method described in our previous study (14). MDA levels were expressed as Thiobarbituric Acid Reactive Substances (TBARS). After the reaction of thiobarbituric acid with MDA, the reaction product was measured spectrophotometrically. Tetramethoxy propane solution was used as a standard.

**Superoxide dismutase (SOD) activity measurement:** CuZn-SOD activity in tissue homogenate was measured by the method as described previously (5). Briefly, each homogenate was diluted 1:400 with 10 mM phosphate buffer, pH 7.00. 25 µL of diluted hemolysate was mixed with 850 µL of substrate solution containing 0.05 mMol xanthine sodium and 0.025 mmol/L 2-(4-iodophenyl)-3-(4-nitrophenol)-5-phenyltetrazolium chloride (INT) in a buffer solution containing 50 mMol CAPS and 0.94 mMol EDTA pH 10.2. Then, 125 µL of xanthine oxidase (80 U/L) was added to the mixture and absorbance increase was followed at 505 nm for 3 minutes against air. 25 µL of phosphate buffer or 25 µL of various stand-

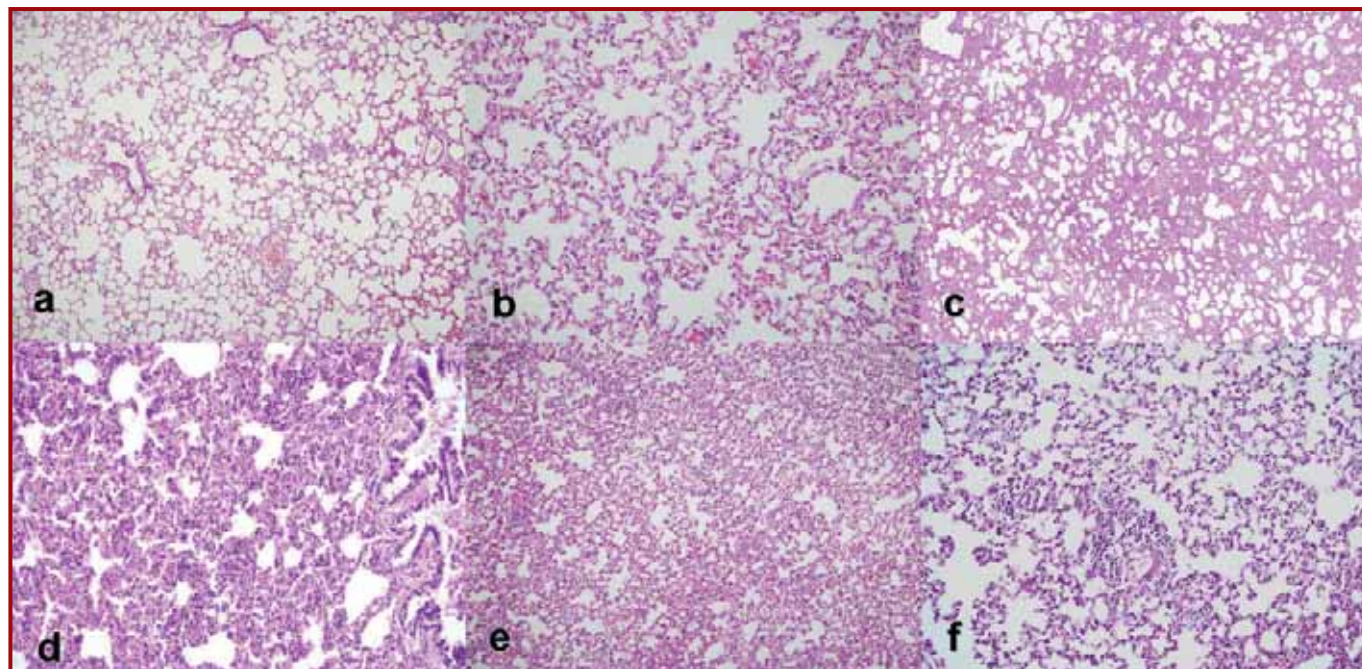
ard concentrations in place of sample were used as blank or standard determinations. CuZn-SOD activity was expressed in U/mg tissue.

**Catalase (CAT) activity measurement:** CAT activity in tissue homogenate was measured by the method of Aebi (15). The reaction mixture was 50 mMol phosphate buffer pH 7.0, 10 mMol H<sub>2</sub>O<sub>2</sub> and homogenate. The reduction rate of H<sub>2</sub>O<sub>2</sub> was followed at 240 nm for 30 seconds at room temperature. Catalase activity was expressed in U/mg tissue.

Statistical analysis was done to analyze the two groups mutually by using Kruskal-Wallis and Mann-Whitney U tests. The results were expressed as the median (min–max), and p<0.05 was assessed as statistically significant.

## Results

**Histopathological evaluation:** Representative histopathological pictures of the study groups are demonstrated in Figure 1. Control animals were presented with normal lung tissue. Alveolar edema, parenchymal congestion, alveolar hemorrhage, interstitial inflammation and bronchiolocentric inflammation were not encountered in the lungs of the control cases. Histopathological evaluation of rat lungs following NM administration revealed that the development of lesions predominated in the parenchymal region. The lung lesions following NM administration were alveolar edema, parenchymal congestion,



**Figure 1.** Histopathological examination of the control group shows normal pulmonary parenchyma (a H&Ex40 and b H&Ex200). One of the cases in NMG group showed dense interstitial inflammation, alveolar collapse, parenchymal congestion and minimal alveolar hemorrhage in the lung parenchyma (c H&Ex40 and d H&Ex200). In the treatment group, a case demonstrated mild interstitial inflammation (e H&Ex40 and f H&Ex200)

alveolar hemorrhage, interstitial inflammation and bronchiolocentric inflammation. In the lungs of PC-treated rats, alveolar edema, alveolar hemorrhage, and inflammatory cell infiltration and airways pathology were also observed (Table I).

There were severe alveolar congestion, interstitial inflammation and bronchial inflammation and many of the alveoli obstruction in NMG. Inflammatory cells were also apparent around bronchial mucosal epithelium and interstitial tissue. Many airways were collapsed. In addition, significant interstitial inflammation was also observed after PC treatment. Lung parenchyma showed inflammation into the airways and alveoli. In the PC treated rats significant less alveolar congestion, alveolar hemorrhage, and airways pathology was observed. The degree of histopathological parameters according to study groups is presented in Table I.

*MDA levels, and GSH-Px, SOD and CAT activities in tissue:* Oxidative stress analysis included MDA level, and SOD, CAT and GSH-Px activity. NM direct exposure caused significantly higher MDA levels, and lower GSH-Px, SOD and CAT activity in lung tissue. On the other hand, PC treatment decreased MDA levels, and SOD, CAT and GSH-Px activities were similar to those of NMG group. (Table II)

## Discussion

Mustard, one of the most important vesicant agents, affects respiratory system and causes some degree of damage on other tissue and organs (5,6,16). Mustards were also reported as a mutagenic, carcinogenic, and cytotoxic agent (16). Current knowledge makes it seem feasible that mustard toxicity comes from oxidative as well as nitrosative stress leading to lipid, protein and DNA damage in the target cell (5). Yaren et al. showed that scavenging peroxynitrite and inhibiting iNOS have similar protective effects. They thought that peroxynitrite may be responsible, at least in part for NM-induced lung toxicity, and peroxynitrite scavengers may be useful in order to prevent mustard toxicity (5). In our study, NM direct exposure caused increased MDA levels, and significantly decreased GSH-Px, SOD and CAT activity in lung tissue. These findings suggest that free oxygen radical damage has an important role in mustard toxicity.

It is well known that PC is a free radical scavenger and it has also anti-thrombotic and anti-inflammatory effects (9,10,17,18). In particular, novel antioxidants can neutralize harmful free radicals and their damaging effects on tissue and organ as well as enhancing the body's antioxidant status (11). Grape seed PCs, a combination of biologically active

**Table I.** Histopathological results of lung tissue after mustard exposure and proanthocyanidine treatment in rats

Groups	n	Alveolar edema			Parenchymal congestion			Alveolar hemorrhage			Interstitial inflammation			Bronchiolocentric inflammation							
		-	1+	2+	3+	-	1+	2+	3+	-	1+	2+	3+	-	1+	2+	3+				
Control group	15	15	0	0	0	15	0	0	0	15	0	0	0	15	0	0	0	15	0	0	0
Nitrogen mustard-only group	15	14	1	0	0	3*	7	4	1	9*	3	2	1	8*	4	3	0	11*	2	1	1
Nitrogen mustard plus proanthocyanidine group	15	15	0	0	0	6**	6	3	0	12**	2	1	0	6**	5	3	1	12**	2	1	0

\*: p<0.001, Nitrogen mustard-only group compared with control group

\*\* : p<0.05, Nitrogen mustard plus proanthocyanidine group compared with nitrogen mustard-only group

**Table II.** Oxidative stress related parameters of the lung tissue after mustard exposure and proanthocyanidine treatment in rats

Groups	n	Malondialdehyde (nmol/mg)*	Glutathione peroxidase (U/mg)*	Catalase (U/mg)*	Superoxide dismutase (U/mg)*
Control group	15	6.87±0.35	0.045±0.0058	0.031±0.0040	0.240±0.030
Nitrogen mustard-only group	15	8.05±0.70**	0.023±0.002**	0.002±0.0004**	0.117±0.040**
Nitrogen mustard plus proanthocyanidine group	15	7.25±0.85***	0.024±0.004	0.002±0.0016	0.102±0.063***

\*: Values are given as mean±standard deviation

\*\* : p<0.001, Nitrogen mustard-only group compared with control group

\*\*\*: p<0.05, Nitrogen mustard plus proanthocyanidine group compared with nitrogen mustard-only group

polyphenolic flavonoids including oligomeric PCs, have been demonstrated to exert a novel spectrum of biological and therapeutic properties against oxidative stress and oxygen free radicals (11,18). Bagchi et al. have demonstrated that GSPE is a potent bioavailable scavenger of free radicals that provides significant protection towards multiple target organs against structurally diverse drug and chemically induced toxic manifestations in rat (100 mg/kg body weight, p.o.) (11). Our study showed that due to its obvious antioxidant effect proanthocyanidine can be an efficient protector against NM. PC treatment decreased MDA levels when compared to non-PC given NMG group. However GSH-Px, SOD and CAT activities were not significantly different in PCG and NMG group. This showed that free radicals were scavenged by PC but SOD, CAT and GSH-Px activities were still lower than CG. It can be concluded that free radicals were not removed completely.

Previous studies have exhibited that the primary airway lesion from mustard is necrosis of the mucosa with later damage to the musculature of the airways (3,4,6). In our study, only one rat had hemorrhagic pulmonary edema in NMG.

Inhalation of mustard gas incites acute respiratory distress syndrome (ARDS) due to hemorrhagic inflammation (6,7). Most deaths are due to secondary respiratory infection (6). Death often occurs between the fifth and tenth day after exposure because of pulmonary insufficiency and infection complicated by a compromised immune response from agent-induced bone marrow damage (3,4). In this study it was found that the main NM-related airway lesions were alveolar edema, alveolar congestion, alveolar hemorrhage, interstitial inflammation and bronchiocentric inflammation.

Right at this point, the major subject we were strongly interested was the level and adequacy of the lung damage. It was because the way we used to induce that damage. It is obvious that many studies about lung damage induced by NM have already been done in time and the results were sufficient. But in none of these studies, rats were directly exposed to vaporized nitrogen mustard; usually they have been exposed to NM solutions intratracheally (1,5). Our exposure method was set to simulate the war field as similar as it can be.

Histopathological evaluation confirmed lung damage with NM exposure in NMG. As these findings were parallel and very similar to the findings of former studies about the same issue, they brought up the adequacy and appropriateness of the method we used to induce a lung damage related to NM (1,5).

PC treatment decreased histopathological changes in PCG. It was shown that free oxygen radical damage has an important role in mustard toxicity. PC, which is a strong free oxygen radical scavenger, has an acceptable effect for decreasing toxic outcomes. Further clinic and experimental studies, with the same and/or other antioxidant agents, could prove their probable protective roles against mustard toxicity.

Indeed, this study includes many variable parameters i.e; exposed NM dose, exposure period, proanthocyanidine administration dose, treatment onset time, etc. Thus for a better treatment protocol, further studies are needed to be done about these parameters.

## References

1. Ucar M, Korkmaz A, Reiter RJ, et al. Melatonin alleviates lung damage induced by the chemical warfare agent nitrogen mustard. *Toxicol Lett* 2007; 173: 124-131.
2. Elsayed NM, Omaye ST. Biochemical changes in mouse lung after subcutaneous injection of the SM2-chloroethyl 4-chlorobutyl sulfide. *Toxicology* 2004; 199: 195-206.
3. Graham JS, Chilcott RP, Rice P, Milner SM, Hurst CG, Maliner BI. Wound healing of cutaneous sulfur mustard injuries: strategies for the development of improved therapies. *J Burns Wounds* 2005; 4: 1-45.
4. Sidell FR, Urbanetti JS, Smith WJ, Hurst CG. Vesicants. In: James H (ed.) *Medical Aspects of Chemical and Biological Warfare*. Borden Institute, 1997: 197-228.
5. Yaren H, Mollaoglu H, Kurt B, et al. Lung toxicity of nitrogen mustard may be mediated by nitric oxide and peroxynitrite in rats. *Res Vet Sci* 2007; 83: 116-122.
6. Chatterjee D, Mukherjee S, Smith MG, Das SK. Signal transduction events in lung injury induced by 2-chloroethyl ethyl sulfide, a mustard analog. *J Biochem Mol Toxicol* 2003; 17: 114-121.
7. Roy SS, Mukherjee S, Kabir S, Rajaratnam V, Smith M, Das SL. Inhibition of cholinephosphotransferase activity in lung injury induced by 2-chloroethyl ethyl sulfide, a mustard analog. *J Biochem Mol Toxicol* 2005; 19: 289-297.
8. Anderson DR, Byers SL, Vesely KR. Treatment of SM (HD)-induced lung injury. *J Appl Toxicol* 2000; 20: 129-132.
9. Li WG, Zhang XY, Wu YJ, Tian X. Anti-inflammatory effect and mechanism of proanthocyanidines from grape seeds. *Acta Pharmacol Sin* 2001; 22: 1117-1120.
10. Sano T, Oda E, Yamashita T, et al. Anti-thrombotic effect of proanthocyanidine, a purified ingredient of grape seed. *Thromb Res* 2005; 115: 115-121.
11. Bagchi D, Sen CK, Ray SD, et al. Molecular mechanisms of cardioprotection by a novel grape seed proanthocyanidine extract. *Mutat Res* 2003; 523: 87-97.



12. Pataki T, Bak I, Kovacs P, Bagachi D, Das DK, Tosaki A. Grape seed proanthocyanidines improved cardiac recovery during reperfusion after ischemia in isolated rat hearts. *Am J Clin Nutr* 2002; 75: 894-899.
13. Aydın A, Orhan H, Sayal A, Özata M, Şahin G, İşimer A. Oxidative stress and nitric oxide related parameters in type II diabetes mellitus: effects of glycemic control. *Clin Biochem* 2001; 34: 65-70.
14. Bulucu F, Vural A, Aydın A, Sayal A. Oxidative stress status in adults with nephrotic syndrome. *Clin Nephrol* 2000; 53: 169-173.
15. Aebi H. Catalase in vitro. In: Packer L (ed). *Methods Enzymol*. Orlando: Academic Press, 1984: 105-126.
16. Dacre JC, Goldman M. Toxicology and pharmacology of the chemical warfare agent sulfur mustard. *Pharmacol Rev* 1996; 48: 289-326.
17. Sharma SD, Katiyar SK. Dietary grape-seed proanthocyanidine inhibition of ultraviolet B-induced immune suppression is associated with induction of IL-12. *Carcinogenesis* 2006; 27: 95-102.
18. Roychowdhury S, Wolf G, Keilhoff G, Bagchi D, Horn T. Protection of primary glial cells by grape seed proanthocyanidine extract against nitrosative/oxidative stress. *Nitric Oxide* 2001; 5: 137-149.