

An extremely rare foreign material in the bladder: a piece of pen

Hamit Ersoy (*), Levent Sağnak (*), Hikmet Topaloğlu (*), Hasan Bakırtaş (*), Erkin Şahin (*),
Ahmet Kiper (*)

Summary

An 19-year-old female patient admitted to our clinic with hematuria and urinary infection due to an unexpected run of a broken head of a simple pencil to urinary bladder during erotic self stimulation. Diagnosis and treatment were discussed under the light of literature.

Key words: Foreign body, treatment, urinary bladder

Özet

Mesane nadir görülen bir yabancı cisim: kalem parçası
Erotik stimülasyon sırasında kullandığı kalem parçası mesane içine kaçan, üriner enfeksiyon ve kanama nedeniyle kliniğimize başvuran 19 yaşında bir bayan hastanın tanı ve tedavisi değerlendirildi. Bu tip olgularda yaklaşım literatür eşliğinde tartışıldı.

Anahtar kelimeler: Yabancı cisim, tedavi, mesane

Introduction

In females, foreign bodies of the urinary bladder are due to self-insertion, iatrogenic causes or migration from neighboring organs. In young females erotic stimulation and in small children curiosity might result in having a foreign body in the bladder. In addition, psychiatric disturbances, dementia or alcohol ingestion might lead to uncontrollable behavior resulting in foreign bodies (1). Iatrogenic foreign bodies do appear during endoscopic interventions or stenting procedures. Foreign bodies due to migration usually originate from neighboring organs and are mainly the intrauterine devices (2).

In the present case we present the pen used for erotic stimulation, which entered the bladder through the urethra. It is of interest as there is no such case in the literature.

Case Report

An 19-year-old single female patient admitted to the hospital with the complaints of severe urinary infection and bleeding. Direct urinary system X-ray demonstrated a foreign body resembling a pen situated in the bladder region. When the patient was questioned, she declared that an uncontrollable behavior resulted in the piece of pen entering the bladder during erotic stimulation informing also that her family was not yet aware of the situation (Figure 1). Cystoscopic examination showed a piece of pen with hardened outer surface in the bladder (Figure 2). Genitourinary examination showed that the patient was virgin. So we concluded that the foreign body had entered through urethra. A decision for an intervention under general anesthesia was given. The bladder was entered with a cystoscope, the foreign body was tried to be approached with a forceps, however, due to the longstanding contact with the urine, its physical structure was hampered and it started falling into pieces, and it was extracted by inserting the tip of the cystoscope to the open end of the pen (Figure

* Ministry of Health, Dışkapı Yıldırım Beyazıt Education Hospital, 3rd Urology Clinic, Ankara, Turkey

Reprint request: Dr. A. Levent Sağnak, Angoraevleri, Altınbel Villaları Hitit Bulvarı, No: 38/A, Beysukent, Ankara, Türkiye
E-mail: leventsagnak@yahoo.com

Date submitted: November 08, 2006

Accepted: January 26, 2007

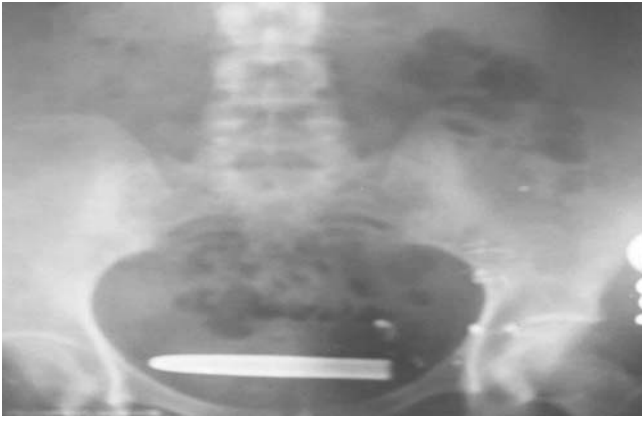


Figure 1. Direct urinary system X-ray

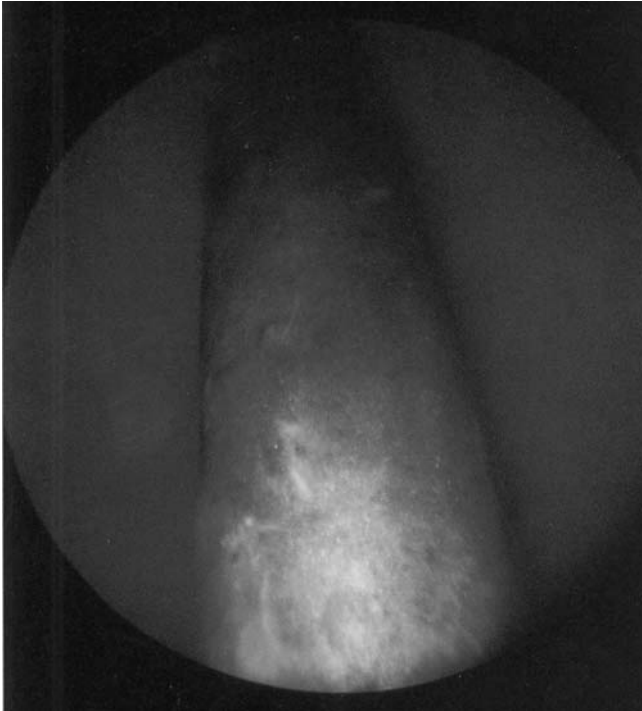

Figure 2. Cystoscopic view of the piece of pen

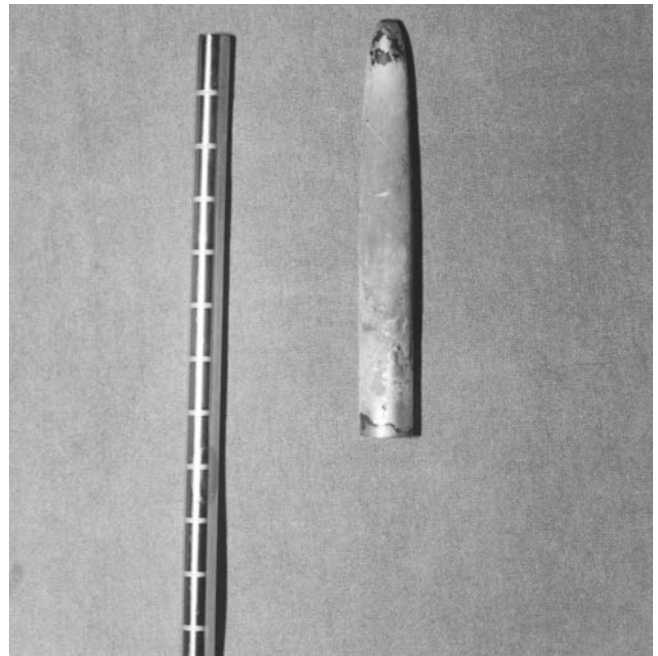


Figure 3. The piece of pen after the extraction

It is very easy to identify foreign bodies. Direct X-ray graphies demonstrate nearly all foreign bodies. When necessary, complementary techniques such as intravenous pyelography and ultrasonography can be employed. For definitive diagnosis, cystoscopy should be performed. Foreign body should be totally extracted with the least possible harm to the urinary bladder and the urethra (5). A forceps will usually be sufficient for catching the object. However as the metallic component of the foreign body was affected due to a long stay in the bladder, it fell into pieces when approached with a forceps. Thus, the piece of pen could be extracted by inserting the tip of the cystoscope to its open end. Depending on the features of the foreign bodies, different techniques may be employed. First choice should be treatment with endoscopic approach. Open surgical approach should be the last resort after all other techniques have proven to be unsuccessful.

3).

Discussion

Intravesical foreign bodies are rare instances concerning the diseases of the lower urinary system. Although both the diagnosis and the treatment are easy, when not considered, the differential diagnosis might create a problem.

When the relevant literature was evaluated, in patients who employ such an approach for sexual satisfaction, shame is a common feeling and they refrain from referring to a physician (1). These patients are frequently confronted with the irritative complaints of the bladder (dysuria, hematuria, frequency) (1,3). In our case, the patient made such an attempt for sexual pleasure.

Although it might seem more difficult, such instances have been reported for males as well. When a literature search was made, several objects, even a watch have been reported in the bladder (1,4).

References

1. Eckford SD, Persad RA, Brewster SF, et al. Intravesical foreign bodies: five year review. *Br J Urol* 1992; 69: 41-45.
2. Atakan H, Kaplan M, Erturk E. Intravesical migration of intrauterine device resulting stone formation. *Urology* 2002; 60: 911.
3. Savioz D, Ludwig C, Leissing C, et al. Repeated macroscopic haematuria caused by intravesical migration of a preperitoneal prosthesis. *Eur J Surg* 1997; 163: 631-632.
4. Bakshi GK, Agrawal S, Shetty SV. An unusual foreign body in the bladder. *J Postgrad Med* 2000; 46: 41-42.
5. Wegner HE, Franke M, Schick V. Endoscopic removal of intravesical pencils using percutaneous nephrolitho-