

# Broken needle in the penis as a complication of intracavernous injection therapy

İlker Akyol (\*), Cüneyt Adayener (\*), Temuçin Şenkul (\*), Kenan Karademir (\*), Kadir Baykal (\*), Cüneyt İşeri (\*)

## Summary

A 74-year-old male applied to the emergency room having a broken needle in his penis. He has been on intracavernous injection therapy for erectile dysfunction and the needle had been broken in that morning. The needle was felt under the soft tissue in his penis and it could be seen on the direct radiography within the dorsolateral part of the penis. The needle was removed under local anesthesia and there was no complication at the operation site. The patient was advised to switch to oral medication for his erectile dysfunction. Manual dexterity of the patients to whom intracavernous injection therapy is advised for erectile dysfunction should be evaluated cautiously, and the importance of correct injection technique should be stressed.

**Key words:** Manual dexterity, erectile dysfunction, intracavernous injection

## Özet

**İntrakavernöz enjeksiyon tedavisinin komplikasyonu olarak penis içinde kırılmış iğne**

Yetmiş dört yaşındaki erkek hasta, ilkyardımcı servisine penisinin içinde kırılmış bir iğne olduğunu ifade ederek başvurdu. Erektile işlev bozukluğu nedeniyle kendi kendine intrakavernöz enjeksiyon tedavisi uygulayan hastanın penisinde iğne palpe edilebiliyor ve direkt grafide iğne penisin dorsolateralinde görülebiliyordu. İğne, lokal anestezi altında çıkarıldı ve operasyon yerinde komplikasyon gelişmedi. Hastaya, erektil işlev bozukluğu için oral tedaviye geçmesi önerildi. Erektile işlev bozukluğunda intrakavernöz enjeksiyon tedavisi önerilen hastaların el becerileri dikkatlice değerlendirilmeli ve doğru enjeksiyon tekniğinin önemi vurgulanmalıdır.

**Anahtar kelimeler:** El becerisi, erektil disfonksiyon, intrakavernöz enjeksiyon

## Introduction

A number of agents, either alone or in combination, have long been used in erectile dysfunction for intracavernous injection therapy; though this was not without serious adverse effects such as priapism, corporeal fibrosis, systemic side effects due to vasodilatory action (e.g. hypotension, tachycardia, pallor, dizziness), painful erection, pain in the injection site and hematoma/ecchymosis (1). Rather high patient drop out rates have also been reported due to various reasons such as unnaturalness of the treatment, and the above-mentioned adverse effects associated with the procedure (1). We herein report a rather unusual complication of intracavernous injection therapy.

## Case Report

A 74-year-old male applied to the emergency room (ER) having a broken needle in his penis. He has been on intracavernous injection therapy (ICIT) for erectile dysfunction (ED) for the past month and he did an injection that morning in the way that he had been taught. The patient reported that the needle of the syringe was broken as he pulled it out of the corpus cavernosum, and the distal part of the needle was stuck in his penis. Physical examination revealed a small area of hyperemia on the left dorsolateral side of the penis and the needle was felt under the soft tissue. A direct radiography showed a linear opacity lying obliquely from outside to deep inside of the corpus cavernosum of the penis (Figure 1). We decided to take the foreign object out and went on with a skin incision under local anesthesia. The broken part of the needle was found under dartos fascia and taken out. This was a 28 gauge needle. There was no bleeding at the site immediately after the removal of the needle. Subcutaneous tissue was closed with running sutures in two layers and the skin was closed with chromic sutures. A tight bandage was applied so as not

\*Department of Urology, GATA Haydarpaşa Teaching Hospital

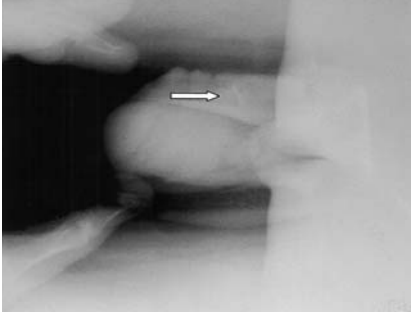
Reprint request: Dr. Cüneyt Adayener, GATA Haydarpaşa Eğitim Hastanesi Üroloji Servisi, Üsküdar-34668, İstanbul

E-mail: cuneytadayener@yahoo.com

Date submitted: June 01, 2006

Accepted: September 29, 2006

to obstruct urine flow and this was removed on the next day. After one week, there was no hematoma nor active bleeding at the surgery site. The patient was advised to switch to oral medication.



**Figure 1.** White arrow showing the needle within the penis (lateral)

### Discussion

The advent of phosphodiesterase (PDE) inhibitors has cut down on the prescription of intracavernous injection therapy and gained popularity rapidly. However PDE inhibitors are often not covered by insurance policies as opposed to less expensive alternative agents used for ICIT. On the other hand, ICIT, being a rather invasive procedure, requires manual dexterity. Our case got his prescrip-

tion elsewhere and was from a lower sociocultural level. The attending physician might have chosen injection therapy as the firstline treatment due to the above-mentioned economical concerns, yet underestimating the importance of patient capability before starting such a treatment. The oblique needle track in the longitudinal direction suggested that the patient's injection technique was wrong. We figured that he inserted the needle obliquely causing it to travel within the corpus cavernosum more than needed, and after completing the injection, he pulled the syringe back in an improper direction which exerted a bending force on the needle which caused it to break before it came out of the penis.

Needle breakage is a very rare complication of ICIT and there are a few case reports in the literature (2-6). It appears that broken part of the needle may be deep inside of the corpus cavernosum, and one may not be able to feel and remove it at first; however, needle may be found at a more superficial location and may be removed later on (2).

As a conclusion, whenever an ICIT is to be started in a patient with ED, manual dexterity should be considered in the first place and the importance of the correct injection technique must be stressed.

### References

1. Evaluation and nonsurgical management of erectile dysfunction and priapism. In: Walsh PC, Retik AB, Vaughan ED, Wein AJ (eds). Campbell's Urology. WB Saunders Company, 2002: 1619-1663.
2. Greenstein A, Sofer M, Chen J. Delayed retrieval of fragment after needle breakage during intracavernous self-injection. J Urol 1997; 157: 953.
3. Moemen MN, Hamed HA, Kamel II, Shamloul RM, Ghanem HM. Clinical and sonographic assessment of the side effects of intracavernous injection of vasoactive substances. Int J Impot Res 2004; 16: 143-145.
4. Park NC, Park HJ. Management of intracavernosal needle breakage during self-injection of vasoactive agent. Int J Impot Res 2003; 15 (Suppl 6): 64.
5. Mark SD, Gray JM: Iatrogenic penile foreign body. Br J Urol 1991; 67: 555.
6. Beer SJ, See WA. Intracorporeal needle breakage: An unusual complication of papaverine injection therapy. J Urol 1992; 147: 148-150.