

Accessory renal arteries and an anomalous testicular artery of high origin

Necdet Kocabiyik (*), Bülent Yalçın (*), Cenk Kılıç (*), Yalçın Kırıcı (*), Hasan Ozan (*)

Summary

During the dissection in a 55-year-old male cadaver, two accessory renal arteries were encountered in the abdominal region. The arteries were originating from left anterolateral aspect of the abdominal aorta and running into the left kidney. Left testicular artery was originating from the superior accessory renal artery. Left testicular artery crossed behind the inferior accessory renal artery. Origins of the superior accessory renal artery, main renal artery and inferior accessory renal artery were 4.8 mm, 14.5 mm and 46 mm below the superior mesenteric artery, respectively. Subsequently, accessory renal arteries run into superior and inferior pole of the left kidney. These kinds of anomalies are important in surgical procedures related to the abdomen, such as renal transplantation, abdominal aortic aneurysm, ureter surgery, vascular pedicles of kidney and in angiographic interventions.

Key words: Accessory renal arteries, vascular variations, renal surgery, renal transplantation

Özet

Aksesuar renal arterler ve yüksek çıkımlı bir testiküler arter
Ellibeş yaşında bir erkek kadavranın abdominal bölge diseksiyonu sırasında,

iki adet aksesuar renal arterle karşılaşıldı. Arterler, aorta abdominalis'in sol anterolateralinden orijin alıyor ve sol böbreğe giriyordu. Arteria testicularis sinistra, sol tarafta superior aksesuar renal arterden çıkıyordu. Arteria testicularis sinistra, inferior aksesuar renal arteri arkasından çaprazlıyordu. Superior aksesuar renal arter, ana renal arter ve inferior aksesuar renal arterin orijinleri, arteria mesenterica superior'un sırasıyla 4.8 mm, 14.5 mm ve 46 mm altındaydı. Sonuçta, aksesuar renal arterler, sol böbreğe üst ve alt ucundan giriyorlardı. Bu anomali, renal transplantasyon, abdominal aortik anevrizma, böbreğin vasküler pedikülleri ve anjiyografik uygulamalar gibi abdomente ilgili cerrahi girişimlerde önemli olarak değerlendirilmelidir.

Anahtar kelimeler: Aksesuar renal arterler, vasküler varyasyonlar, renal cerrahi, renal transplantasyon

Introduction

The renal and gonadal arteries usually arise from the anterolateral or lateral aspect of the abdominal aorta (1-3). The testicular artery usually arises from the abdominal aorta at the level of the second lumbar vertebra, 2.5-5 cm below the renal artery (4). In the abdomen, the testicular artery supplies the perirenal fat, ureter and iliac lymph; in the inguinal canal it supplies the cremaster muscle (2). Variations relating to origin, course and number of these arteries have been reported in a number of studies (2-7). The embryological bases for these variations have also been well established. From the published studies and reports

about accessory renal arteries, it can be concluded that the average rate of occurrence is approximately 30% (8).

In this case, we emphasize that the presence of two accessory renal arteries supplying to the kidney is not only of academic interest but may also be of practical importance either for the correct interpretation of radiological examinations or for surgical interventions in this region. Testicular arterial anatomy has been well studied because of its importance in testicular physiology and surgery (3). It is, therefore, of considerable practical importance for a surgeon to be as careful in dissecting peripheral fat over the renal polus as in dissecting the hilar region (9).

Case Report

During the dissection in a 55-year-old male cadaver, two accessory renal arteries were encountered on the left side of the abdominal aorta (Figure 1).

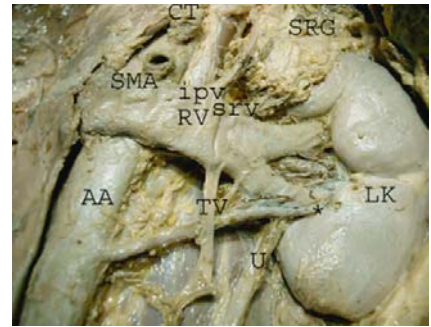


Figure 1. *: The accessory renal artery (inferior), LK: left kidney, RV: renal vein, RA: renal artery, TV: testicular vein, SMA: superior mesenteric artery, U: ureter, AA: abdominal aorta, CT: coeliac trunk, ipv: inferior phrenic vein, srv: suprarenal vein, SRG: suprarenal gland

*GATA Anatomi AD

Ayrı basım isteği: Dr. Necdet Kocabiyik, GATA Anatomi AD, Etilik-06018, Ankara
E-mail: nkocabiyik@gata.edu.tr

Makalenin geliş tarihi: 29.09.2004

Kabul edilme tarihi: 21.02.2005

Two accessory renal arteries originating from the left lateral part of the abdominal aorta and run into left kidney. Superior accessory renal artery was arising from 4.8 mm below the superior mesenteric artery and running into the superior pole of the left kidney. Main renal artery was arising from 14.5 mm below the superior mesenteric artery and running into the middle pole of the left kidney. Inferior accessory renal artery was arising from 46 mm below the superior mesenteric artery and running into the inferior pole of the left kidney (Figure 2).

A schematic representation of the case is shown in Figure 3. Left testicular artery was originating from the superior accessory renal artery. Main renal artery and inferior accessory renal artery crossed behind the left testicular artery. The main renal artery and accessory renal artery on the right were already cut in the autopsy (Figures 2,3).

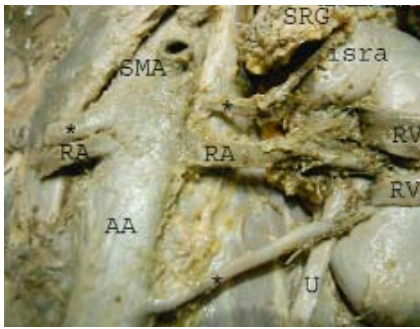


Figure 2. *: The accessory renal artery, RV: renal vein, RA: renal artery, TV: testicular vein, TA: testicular artery, SMA: superior mesenteric artery, U: ureter, isra: inferior suprarenal artery, SRG: suprarenal gland

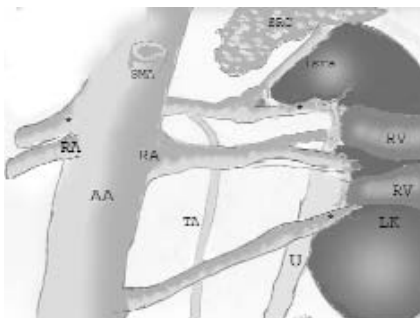


Figure 3. Schematic illustration showing the variation. *: the accessory renal artery, RV: renal vein, RA: renal artery, TV: testicular vein, TA: testicular artery, SMA: superior mesenteric artery, U: ureter, isra: inferior suprarenal artery, SRG: suprarenal gland

Discussion

Certain knowledge of the embryology of the renal vasculature and structural development of the kidney is essential to the understanding of the multitude of anomalies that may occur. With the complex development of the kidneys through the three stages of pronephros, mesonephros and metanephros, and the migration of the kidney from the pelvis to the lumbar region, along with its longitudinal location and simultaneous acquisition of a vascular supply, there is reason to understand why the possibility for anomalous development in the kidney may be greater than for other organs within the body (10).

Renal vasculature may be studied at various levels, commencing with the principal and accessory renal arteries. Their primary patterns of branching and areas of distribution suggest the presence of vascular segmentation. From the primary stems branch lobar, interlobar, arcuate and interlobular arteries, afferent and efferent glomerular arterioles and cortical intertubular capillary plexuses, cortical venous radicles drain them and also the vasa recta and associated capillary plexuses of the medulla to the renal vein (2).

Variations in the origin, course and branches of the testicular arteries are attributed to their embryologic origin. During embryon development, the lateral splanchnic arteries on each side supply the mesonephros, metanephros, the testis or ovary, and the suprarenal gland; all these structures develop, in whole or part, from the intermediate mesenchyme of the mesonephric ridge. One testicular or ovarian artery and three suprarenal arteries persist on each side (2).

Machnicki and Grzybiak examined the variations of the testicular arteries in fetuses and adults. Four main types of testicular arteries were identified according to their site of origin from aorta or renal arteries: 1- a single testicular artery arising from the aorta (type A), 2- a single testicular artery arising from the renal artery (type B), 3- two testicular arteries arising from the aorta and penetrating the same gonad (type C), and 4- two arteries penetrating the testis, one arising from the aorta and the other from the renal artery (type D) (11).

Shinora et al. described the left testicular artery originated from the aorta as high as one cm cranial to the origin of the

left inferior phrenic artery (6). In the study of Notkovich including 405 testicular or ovarian arteries, the gonadal arteries of renal origin were found in 14 percent, taking their origin from the principal renal artery from its branches or from an accessory renal artery, as well (12). In our case, the left testicular artery was originating from the superior accessory renal artery.

Accessory renal arteries usually arise from the aorta above or below the main renal artery and follow it to the renal hilum. Higher or lower origins are not uncommon, an accessory artery or leash of arteries passing to the superior or inferior renal pole are possible. They are regarded as persistent embryonic lateral splanchnic arteries. Accessory vessels to the inferior pole cross anterior to the ureter and may, by its obstruction, cause hydronephrosis. Rarely, accessory renal arteries arise from the celiac or superior mesenteric arteries near the aortic bifurcation or from the common iliac arteries (2).

Some authors (2,12,13) state that similar anomalies in their particular interest may be important from the clinical point of view in that they may cause; a) Varicocele (ovarian varicocele in female) secondary to compression of the renal vein by an arched gonadal artery, b) Hydronephrosis due to occlusion or compression of the ureter by an inferior polar artery, c) Nephroptosis and malrotation of the kidney associated with an inferior polar artery, d) Arterial hypertension because of the constriction of renal arteries and subsequent renal ischemia, e) The risk of infarction in a kidney during urologic or oncologic surgical interventions and renal transplantations. As inferior polar artery is a segmental artery, the erroneous ligation or division of it is clearly hazardous to result in the necrosis of a segment of the kidney tissue (2,12,13).

The reported incidence of additional renal arteries has a wide range between 8.7% and 75.7%, and they can cause hydronephrosis by compressing the ureter (2,14,15). This anomaly is important in surgical procedures related to the posterior abdominal wall, renal transplantation, abdominal aortic aneurysm, ureter surgery, the vascular pedicles of kidney. It may also be of practical importance for correct interpretation of roentgenographic examinations in angiographic proce-

dures. In our case, the relationship between the accessory renal artery and testicular artery may be important for surgical view; especially in operative or post-operative bleeding. Also, the potential collateral circulation between the abdominal aorta and left renal artery may be important in the obstruction of the renal circulation.

References

1. Bauer FW. The aortic origin of renal arteries. *Arch Path* 1968; 86: 230-233.
2. Williams PL, Bannister, LH, Berry MM, Collins P, Dyson M, Dussek JE, Ferguson MW. *Gray's Anatomy*. 38th ed. London: Churchill Livingstone, 1995: 204, 318, 326, 361, 1548, 1557, 1559, 1826, 1827, 1920.
3. Çiçekçibaşı AE, Salbacak A, Şeker M, Ziylan T, Büyükmumcu M, Uysal İİ. The origin of gonadal arteries in human fetuses: anatomical variations. *Ann Anat* 2002; 184: 275-279.
4. Brohi RR, Sargon MF, Yener N. High origin and unusual suprarenal branch of a testicular artery. *Surg Radiol Anat* 2001; 23: 207-208.
5. Ozan H. An unusual course of the right renal artery associated with an anomalous inferior vena cava. *Ann Anat* 1998; 180: 569-572.
6. Shinohara H, Nakatani T, Fukuo Y, Morisawa S, Matsuda T. Case with a high positioned origin of the testicular artery. *Anat Rec* 1990; 226: 264-266.
7. Malcic-Gürbüz J, Akalin A, Gümüştü B, Çavdar S. Clinical implications of concomitant variations of the testicular, suprarenal and renal veins: a case report. *Ann Anat* 2002; 184: 35-39.
8. Nathan H. Aberrant renal artery producing developmental anomaly of kidney associated with unusual course of gonadal (ovarian) vessels. *J Urol* 1963; 89: 570-572.
9. Nathan H, Glezer I. Right and left accessory renal arteries arising from a common trunk associated with unrotated kidneys. *J Urol* 1984; 132: 7-9.
10. Olsson O, Wholey M. Vascular abnormalities in gross anomalies of kidneys. *Acta Radiol Diagn* 1964; 2: 420-432.
11. Machnicki A, Grzybiak M. Variations in testicular arteries in fetuses and adults. *Folia Morphol (Warsz)* 1997; 56: 277-285.
12. Notkovich H. Variation of the testicular and ovarian arteries in relation to the renal pedicle. *Surg Gynecol Obstet* 1956; 103: 487-495.
13. Ozan H, Gümüştalan Y, Önderoğlu S, Şimşek C. High origin of gonadal arteries associated with other variations. *Ann Anat* 1995; 177: 157-160.
14. Singh G, Ng YK, Bay BH. Bilateral accessory renal arteries associated with some anomalies of the ovarian arteries: a case study. *Clin Anat* 1998; 11: 417-420.
15. Moore KL, Dalley AF. *Clinically Oriented Anatomy*. 4th ed. Philadelphia: Lippincott Williams and Wilkins, 1999: 202-208, 279-289.