

VARIATIONS OF THE BRANCHES OF THE CELIAC TRUNK(✧)

**Dr. Bülent YALÇIN (*), Dr. Necdet KOÇABIYIK (*), Dr. Fatih YAZAR (*),
Dr. Hasan OZAN (*), Dr. Ömer ÖZDOĞMUŞ (**)**

Gülhane Tıp Dergisi 46 (2) : 163 - 165 (2004)

ÖZET

Truncus Coeliacus'un Dallarının Varyasyonları

25 yaşında Türk kadın kadavranın abdominal duvarının arka bölümünde sol a.phrenica ve sol a.suprarenalis media'da varyasyon tespit edildi. Sol a.phrenica ile sol a.gastrica, ortak bir gövdeyle truncus coeliacus'tan orijin alıyorlardı. Sol a.suprarenalis media'da truncus coeliacus orijinliydi. Bu nedenle, truncus coeliacus a.hepatica, a.splenica, a.suprarenalis media ve a.gastrica sinistra ile a.phrenica inferior'un birlikte çıktığı ortak gövdeden oluşuyordu. Olgu cerrahi önemi açısından değerlendirildi.

Anahtar Kelimeler: A.Phrenica Inferior, A.Suprarenalis Media, Truncus Coeliacus.

SUMMARY

A variation of the left inferior phrenic and left middle suprarenal arteries was detected in the back of the abdominal wall of a 25-year-old Turkish woman cadaver. Left inferior phrenic artery and left gastric artery originated from the celiac trunk via a common trunk. Left middle suprarenal artery also derived directly from the celiac trunk. Therefore the celiac trunk was formed by common hepatic artery, splenic artery, middle suprarenal artery and a common trunk. The case was evaluated in the point of surgery.

Key Words: Inferior Phrenic Artery, Middle Suprarenal Artery, Celiac Trunk.

(*) Department of Anatomy, Gulhane Military Medical Academy, Ankara, Turkey

(**) Department of Anatomy, Faculty of Medicine, Marmara University, Istanbul, Turkey

Reprint Request : Dr. Bülent YALÇIN, GATA Anatomi Ana Bilim Dalı 06018 Etlik/Ankara

e-mail: byalcin@gata.edu.tr

Kabul Tarihi : 24.02.2004

(✧) 7. Balkan Askeri Tıp Kongresi'nde poster olarak yayınlanmıştır.

INTRODUCTION

During the normal development, both dorsal aortas give rise to many omphalomesenteric (ventral segmental) arteries. Fusion of the dorsal aorta develops in about four weeks, and regression of multiple omphalomesenteric arteries progresses shortly thereafter. The dorsal aorta gives off segmental branches to the digestive tube (ventral splanchnic arteries), to the mesonephric ridge (lateral splanchnic arteries) and intersegmental branches to the body wall (somatic arteries) (1). Anatomic variations involving the visceral arteries are common (2,3). Also variation of the branches of the celiac trunk were reported by many authors (4,5).

While vascular anomalies are usually asymptomatic, they may become important in patients undergoing diagnostic angiography for gastrointestinal bleeding, celiac axis compression syndrome, or prior to an operative procedure or transcatheter therapy.

CASE REPORT

During the dissection of the posterior abdominal wall of a 25-year-old woman cadaver, it was encountered that the celiac trunk branched unusual manner. The celiac trunk arose from the ventral surface of the abdominal aorta at the level of the intervertebral disc between T12 and L1 vertebrae. The muscular fibers of the left and right crus of the diaphragm were closely related to the celiac trunk and to its branches. The celiac trunk was formed by the common hepatic artery, splenic artery, left middle suprarenal artery and the common trunk, constituted by the left gastric and left inferior phrenic arteries (Fig. 1, 2), had an external diameter of 8.8 mm.

Its length from its origin to the point where the celiac trunk gave off main branches was measured as 7.8 mm. The common trunk was the largest branch of the celiac trunk and had an external diameter of 5.8 mm. Its length from its origin to the point where it gave off the left gastric and left inferior phrenic arteries was 3.6 mm. In its origin, the diameter of the left gastric artery (4.7 mm) was wider than the left

inferior phrenic artery (3.1 mm). The left gastric artery ascended to the cardiac part of the stomach and supplied the left side of the lesser curvature and the abdominal part of the esophagus. To show the celiac trunk and its branches we moved the stomach upward, and completely removed the pancreas. The left inferior phrenic artery run obliquely to the left crus of the diaphragm. Over the left suprarenal gland it gave off 2 branches to the superior portion. Left middle suprarenal artery was the first and the smallest (2.4 mm in diameter) branch of the celiac trunk, and arose from the lateral surface of the aorta. The spleen was moved downward to show course of it. After originating left middle suprarenal artery ascended laterally and obliquely over the vertebral column. At the body of the T12 vertebra, left middle suprarenal artery entered into the middle portion of the left suprarenal gland. Its length and diameter were measured as 35 and 2 mm, respectively. The inferior portion of the suprarenal gland was supplied by the inferior suprarenal artery originating from the proximal part of the left renal artery.

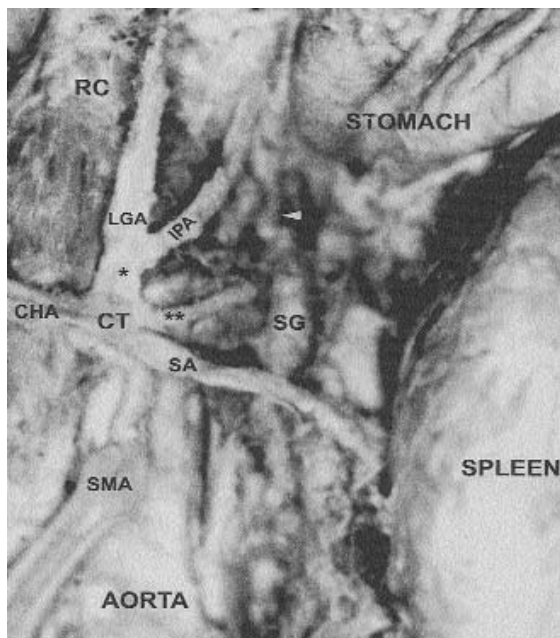


Figure 1. The photograph of the celiac trunk and its branches (left renal vein and pancreas removed).
 CT: celiac trunk; SA: splenic artery; LGA: left gastric artery; CHA: common hepatic artery; IPA: left inferior phrenic artery; SMA: superior mesenteric artery; RC: right crus of the diaphragm; SG: left suprarenal gland; *: common trunk; **: left middle suprarenal artery; white arrowhead: left superior suprarenal arteries.

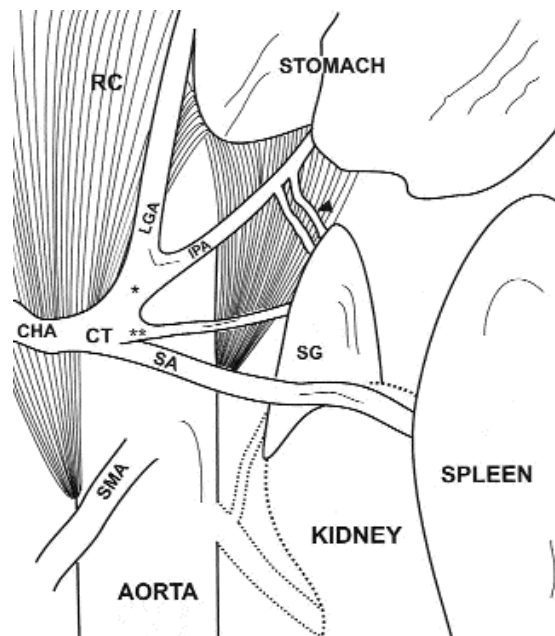


Figure 2. Schematic drawing of the celiac trunk and its branches.

CT: celiac trunk; SA: splenic artery; LGA: left gastric artery; CHA: common hepatic artery; IPA: left inferior phrenic artery; SMA: superior mesenteric artery; RC: right crus of the diaphragm; SG: left suprarenal gland; *: common trunk; **: left middle suprarenal artery; black arrowhead: left superior suprarenal arteries.

DISCUSSION

The variations of the celiac trunk were different. Some of them were related to its branches such as in our case. Other variations were related to its diameter, length or location. Yüksel et al. (6) stated multiple variations that included an extremely long celiac trunk, an inferior phrenic trunk (as one of the branches of the celiac trunk) and an aberrant right hepatic artery derived from the superior mesenteric artery. Vandamme and Bonte (4) observed the absence of the celiac trunk in 1.25% of their series. Piano et al. (7) stated that the right and left inferior phrenic arteries occasionally originated as a common trunk from the aorta, celiaco-mesenteric system or adreno-renal system. He observed that inferior phrenic arteries were usually paired (left and right) and their origin were summarised as follows; a) the aorta itself (61.6%), b) ventro-visceral arteries (celiaco-mesenteric system of the aorta) including the celiac trunk (28.2%), and left gastric artery (2.9%), c) the latero-visceral arteries (adreno-renal system of the aorta) including the middle adrenal artery (2.9%) and renal artery (4.3%). Cavdar et al. (8) reported a case, in

which the left inferior phrenic artery and the left gastric artery arose from the long celiac trunk (4.3 cm) via a common trunk. In our case, the common trunk was observed, too, but there was also the left middle suprarenal artery, arising from the celiac trunk.

Manso et al. (9) reported that the variation of the middle suprarenal artery was not rare although it generally originated from the abdominal aorta. They also said that this artery may originate from right or left inferior phrenic arteries, inferior or superior suprarenal arteries, superior mesenteric artery, right renal artery, celiac trunk and left renal artery. According to their observations, the number of the left or right middle suprarenal artery was generally one, and rarely originated from the celiac trunk (3.3 %). Okada et al. (10) described a case of absence of the celiac trunk in which the left middle suprarenal artery gave off the inferior phrenic artery, and the left middle suprarenal artery had a common arterial stem with the inferior phrenic and the aberrant renal arteries.

In our case, the variation of the branches of the celiac trunk may be extreme because the embryological development of the paired inferior phrenic artery and middle suprarenal artery (lateral splanchnic artery) had come together with the unpaired visceral segmental artery.

In our opinion; arterial variations should not be ignored during the abdominal operative procedures. Because many of the complications could be avoided with the accurate knowledge of the anatomic variations; we believe that, this case will take its place in the literature and play a significant role in the surgical intervention in the abdominal region and also in angiographies.

REFERENCES

1. Sadler, T.W.: *Langman's Medical Embryology*. Baltimore, Williams&Wilkins, 1985, p. 196-205.
2. Naidich, J.B., Naidich, T.P., Sprayregen, S.: *The origin of the left gastric artery*. *Radiology* 126:623-626, 1978.
3. Guadagni, S., Gola, P., Marsili, L.: *Arterial vasculature of the stomach oncologic gastrectomies*. *Surg Radiol Anat* 17:269-276, 1995.
4. Vandamme, J.P., Bonte, J.: *The branches of a coeliac trunk*. *Acta Anat* 122:110-114, 1985.
5. Yildirim, M., Ozan, H., Kutoglu, T.: *Left gastric artery originating directly from the aorta*. *Surg Radiol Anat* 20:303-305, 1998.
6. Yüksel, M., Yalin, A., Weinfeld, A.B.: *Concurrent anomalies of the abdominal arteries: an extremely long coeliac trunk, an inferior phrenic trunk, and an aberrant right hepatic artery*. *Kaibogaku Zasshi* 73:497-503, 1998.
7. Piano, D.X., Ohtsuka, A., Murakami, T.: *Typology of abdominal arteries, with special reference to inferior phrenic arteries and their oesophageal branches*. *Acta Med Okayama* 52:189-96, 1988.
8. Cavdar, S., Gurbuz, J., Zeybek, A., Sehirli, U., Abik, L., Ozdogmus, O.: *A variation of celiac trunk*. *Acta Anat Nippon* 73(5):505-508, 1998.
9. Manso, J.C., Didio, L.J.A.: *Anatomical variations of the human suprarenal arteries*. *Ann Anat* 182:483-488, 2000.
10. Okada, S., Ohta, Y., Shimizu, T., Nakamura, M., Yaso, K.: *A rare anomalous case of absence of the celiac trunk-the left gastric, the splenic and the common hepatic arteries arose from the abdominal aorta independently*. *Okajimas Folia Anat Jpn* 60:65-72, 1983.