

Case Report

GIANT CYSTITIS CYSTICA SIMULATING BLADDER TUMOR AT ULTRASONOGRAPHY

Dr. Yusuf KİBAR (*), Dr. Selahattin BEDİR (*), Dr. Fahri SÜMER (*),
Dr. Ali AVCI (*), Dr. Melih ALÖMEROĞLU (**),
Dr. Bahri ÜSTÜNSÖZ (***), Dr. Yaşar ÖZGÖK (*)

Gülhane Tıp Dergisi 45 (3) : 285 -286 (2003)

ÖZET

Ultrasonografide Mesane Tümörünü Taklit Eden Dev Sistitis Sistika

Burada üriner enfeksiyonu bulunmaksızın rekürren işeme semptomları olan ve ultrasonografide, mesane tümörünü taklit eden bir cystitis cystica (CC) olgusu sunulmaktadır. Kitlenin transüretral rezeksiyonu yapılmış ve histopatolojik inceleme cystitis cystica olarak rapor edilmiştir. CC'nın intravesikal yumuşak doku kitlelerinin sonografik ayırıcı tanısında yer alması gerektiğini düşünmekteyiz.

Anahtar Kelimeler: Cystitis Cystica, Mesane.

SUMMARY

Here we report on a patient with recurrent irritative voiding symptoms without urinary tract infection where ultrasonographic investigation simulated as bladder tumor. Transurethral resection of the mass was carried out and histopathology revealed cystitis cystica (CC). So, we suggest that CC should be added to the sonographic differential diagnosis of intravesical soft tissue masses.

Key Words: Cystitis Cystica, Bladder.

CASE REPORT

A 50-year-old woman was admitted to our department with a year history of urgency, dysuria and pollakiuria and a previously performed a transvaginal ultrasonography (US) of the bladder demonstrating a solid, broad-based echogenic intravesical mass protruding inside from the dome of the bladder (Figure 1). Urine culture and cytology as well as routine urine and blood examinations, serum biochemistry profiles were all unremarkable. Computerized

Tomography (CT) confirmed the above finding (Figure 2) and a cystoscopy under general anesthesia was undertaken and a lesion located on the dome of the bladder was noted. No areas of irritation were seen on the bladder wall surrounding the lesion. A biopsy of the lesion was done and histopathological examination revealed cystitis cystica (Figure 3).

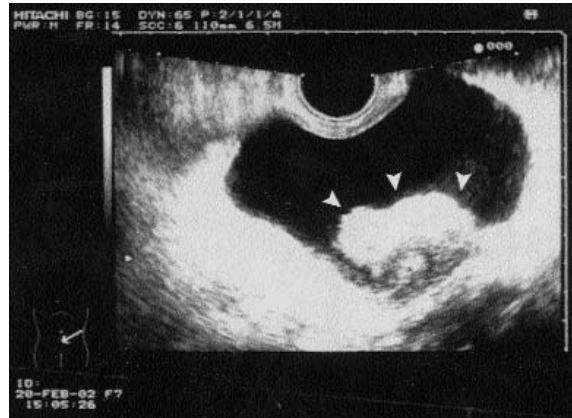


Figure 1: Transvaginal ultrasonography (US) of the bladder demonstrating a solid, broad-based echogenic intravesical mass protruding inside from the dome of the bladder.

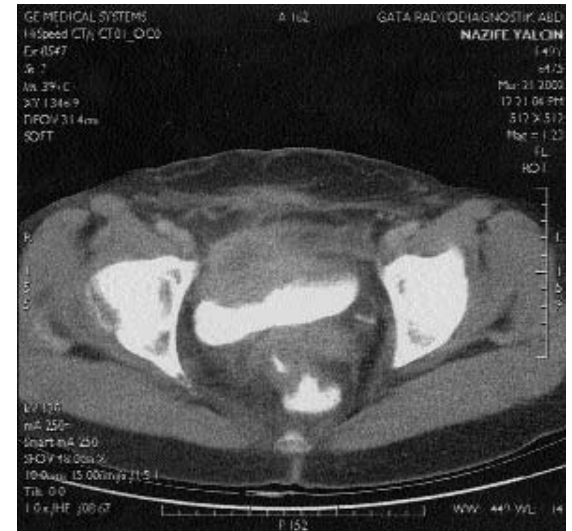

Figure 2: CT of the mass demonstrating a solid, broad-based, irregular diffusely echogenic intravesical mass locating on the dome of the bladder.

(*) GMMA Department of Urology

(**) GMMA Department of Pathology

(***) GMMA Department of Radiology

Reprint Request: Dr. Fahri SÜMER, Gülhane Askeri Tıp Akademisi, Üroloji AD., Etilik, Ankara, TURKEY, 06018

Kabul Tarihi: 26.05.2003

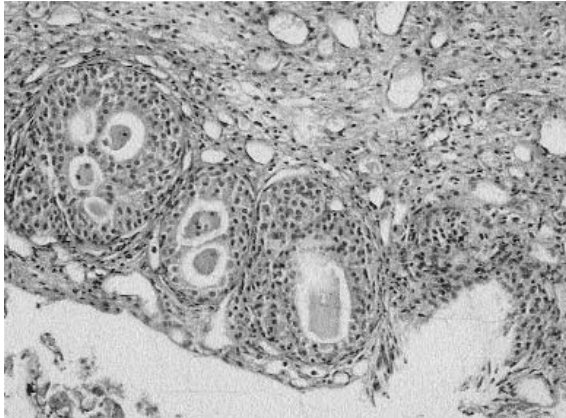


Figure 3: Histopathological examination with areas of cystitis cystica, and glandularis, and von Brunn's nests.

3 weeks after the operation transurethral resection of the mass was carried out having had little effect on the symptoms.

DISCUSSION

CC is a rare disease, caused by metaplasia of the vesical submucosa, probably related to a chronic irritative factor (1).

Diagnosis of CC is mainly based on the pathoanatomical study of the biopsy obtained following endoscopic resection (2). The signs and symp-

toms are varied and show a clear relationship to the distribution and extension of the cysts. Treatment is based on the removal of irritative factors (2).

CC has the same clinical features with simple cystitis but its major pseudoneoplastic form may be mistaken for bladder tumor. The diagnosis is essentially histological. Treatment is usually based on the eradication of the irritative factors (1). Conservative treatment and TUR of the lesions had no effect on the symptoms (3).

CC is a nonspecific benign inflammatory process of the bladder mucosa largely confined to the trigone. This edematous mucosa produces an intravesical mass that may be visualized with sonography simulating bladder tumor. Definitive diagnosis is easily made at cystoscopy and biopsy of the lesion. So, CC should be added to the sonographic differential diagnosis of intravesical soft tissue masses.

REFERENCES

1. El Moussaoui, A., Dakir, M., Sarf, I., Aboutaieb, R., Zamiati, S., Benjelloun, S.: Cystitis cystica glandularis. A study of 2 cases. *Ann Urol (Paris)* 1997; 31(4): 195-198
2. Varo Solis, C., Bachiller Burgos, J., Baez, J.M., et al.: Glandular cystic cystitis. *Actas Urol Esp* 2000 Jul-Aug; 24(7): 594-598
3. Samdal, F., Brevik, B., Halgunset, J.: Cystitis cystica treated with the neodymium-YAG laser. Case report. *Scand J Urol Nephrol* 1991;25(2):163-164