

THE OSTRICH: AN EXCELLENT TENDON SOURCE FOR THE BIOMECHANICAL STUDIES

Dr. Günhan KARAKURUM (*), Dr. Akif GÜLEÇ (*),
Dr. Orhan BÜYÜKBEBECİ (*), Dr. Erdoğan KARADAĞ (*)

Gülhane Tıp Dergisi 45 (2) : 180 - 181 (2003)

ÖZET

Devekuşu: Biyomekanik Çalışmalar için Mükemmel Bir Tendon Kaynağı

Devekuşu ayağının fleksör tendon anatomisini tanımlayan ve özellikle yeni dikiş tekniklerini test etmekte kullanılan biyomekanik deneylere uygunluğunu vurgulayan bir ön çalışma sunuyoruz. Üç matür devekuşundan elde edilen ayaklar üzerinde diseksiyon yapılarak tendon anatomisi tanımlandı. Her ayaktan, uzunluğu 25 cm olan ve insan tendonlarıyla benzer çapta 4 tendon spesmeni elde edildi.

Anahtar Kelimeler: Devekuşu Tendonları, Biyomekanik Tendon Deneyleri.

SUMMARY

We present a preliminary study describing the flexor tendon anatomy of the ostrich foot with special emphasis on its eligibility for the biomechanical experiments carried out to test new suture designs. Feet obtained from three mature ostriches were dissected and the anatomic features were described. Four tendon specimens each with 25 cm of length and with comparable diameter to the human tendons were obtained from each foot.

Key Words: Ostrich Tendons, Biomechanical Tendon Experiments.

INTRODUCTION

Biomechanical studies carried out to introduce new methods of tendon repair remain one of the most popular subjects throughout the literature of hand surgery. These experiments are usually performed on the tendons of dogs (1), rabbits (2,3,4), chickens (5,6), cadavers (7,8). Neither the quality nor the quantity of the tendons of the aforementioned animals are sufficiently similar with the human ten-

dons. The cadaver tendons on the other hand, are usually limited in number, difficult to preserve during long lasting studies and are likely to change consistency and thus the biomechanical properties in case preservation is considered.

We present, for the first time, the flexor tendons of the ostrich, as an excellent source of tendons with good quality, more than adequate length and with comparable diameter to the human counterpart.

MATERIALS and METHODS

Anatomic dissection was performed on the legs and feet of three mature ostriches. These specimens were obtained from the animals which were already sacrificed by the farmers who feed them.

Anatomy: The skin was peeled off to demonstrate the details of tendon anatomy. The ostrich has two digits each with 4 phalanges. The greater toe has three flexor tendons. The most superficial one inserts into the base of the 2nd phalanx and to the condyles of the 1st phalanx. The intermediate tendon and the deep one insert into the bases of the 3rd and the distal-most phalanges, respectively. There is a strong pulley system at the base of the 1st phalanx enclosing the 3 flexor tendons. Additional pulleys exist on the flexor sides of the first interphalangeal joint, the 3rd interphalangeal joint and along the 3rd phalanx. The lesser toe has two flexor tendons. The deep one is much smaller in size and it inserts to the distal-most phalanx after piercing the superficial one at the level of the proximal phalanx. The lateral slip of the superficial flexor terminates at the base of the 2nd phalanx. The medial slip, however, continues distally to insert to the base of the 3rd phalanx, much like as the intermediate flexor of the greater digit. The pulley system is the same with that of the greater toe.

The flexor tendons of both digits blend into a single conjoint tendon at the lower leg and continue so up to the level of the knee. The components of this conjoint tendon are so loosely arranged that they are clearly visible and may be easily separated (Fig. 1). Thus, four tendon specimens each with a length of about 25 cm and a diameter of 3 to 8 mm are obtained (Fig. 2).

(*) Gaziantep University, Department of Orthopaedic Surgery and Traumatology

Reprint Request: Dr. Günhan KARAKURUM, Gaziantep Üniversitesi, Ortopedi ve Travmatoloji AD.

27060 Gaziantep, Türkiye

Kabul Tarihi: 8.5.2003

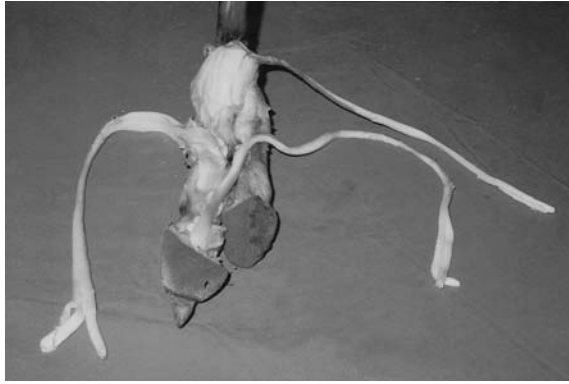


Fig. 1: The ostrich foot shown from the plantar side with the flexor tendons partially separated.

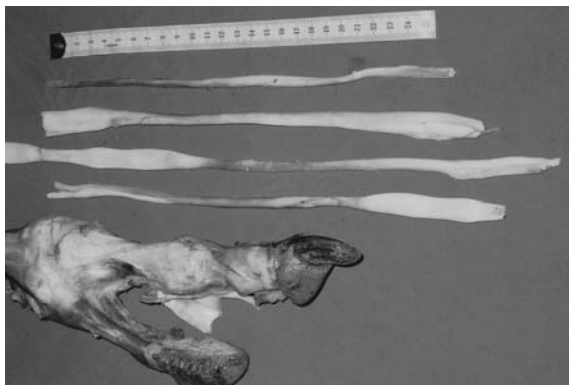


Fig. 2: The available tendons are shown. Notice the length and diameter of the tendons.

DISCUSSION

The ostrich is the only viable commercially available ratite bird which is regarded as a poultry (9). It has been extensively studied particularly within the scope of veterinary medicine with regard to its common infections (10), visceral problems (11), cardiovascular properties (12). We are not aware of any studies performed on its foot tendon anatomy and any study subjecting it to biomechanical tendon testing for the purpose of hand surgery.

However, the ostrich is a valuable source of excellent quality and quantity of tendons. Its toe flexor tendons are so long that they can be attached with ease to the clamps of commonly used tensometers. Furthermore, it is readily available, since its farming has become increasingly widespread throughout the world.

The tendons of the ostrich are very suitable for reliable purchase of commonly used suture material. This fact gains significance in testing the strength of the newly designed suture techniques. As the tendon adhesions remain a challenge to the hand surgeons,

new methods of tendon repair are supposed to keep evolving. The ostrich seems to be rewarding as a source of tendons for these ongoing studies.

REFERENCES

1. Hatanaka, H., Zhang, J., Manske, P. R.: An in vivo study of locking and grasping techniques using a passive mobilization protocol in experimental animals. *J Hand Surg (Am)* 25(2): 260-69, 2000.
2. Moro-oka, T., Miura, H., Mawatari, T., Kawano, T., Nakanishi, Y., Higaki, H., Iwamoto, Y.: Mixture of hyaluronic acid and phospholipid prevents adhesion formation on the injured flexor tendon in rabbits. *J Orthop Res* 18(5): 835-40, 2000.
3. Ozgenel, G. Y., Samli, B., Ozcan, M.: Effects of human amniotic fluid on peritendinous adhesion formation and tendon healing after flexor tendon surgery in rabbits. *J Hand Surg (Am)* 26(2): 332-9, 2001.
4. Komurcu, M., Akkus, O., Basbozkurt, M., Gur, E., Akkas, N.: Reduction of restrictive adhesions by local aprotinin application and primary sheath repair in surgically traumatized flexor tendons of the rabbit. *J Hand Surg (Am)* 22(5): 826-32, 1997.
5. Moran, S. L., Ryan, C. K., Orlando, G.S., Pratt, C. E., Michalko, K. B.: Effects of 5-Fluorouracil on flexor tendon repair. *J Hand Surg (Am)* 25(2): 242-51, 2000.
6. Isik, S., Ozturk, S., Gurses, S., Yetmez, M., Guler, M. M., Selmanpakoglu, N., Gunhan, O.: Prevention of restrictive adhesions in primary tendon repair by HA-membrane: Experimental research in chickens. *Br J Plast Surg (England)* 52(5): 373-9, 1999.
7. Miller, L., Mass, D. P.: A comparison of four repair techniques for Chamber's chiasma flexor digitorum superficialis lacerations: Tested in an in vitro model. *J Hand Surg (Am)* 25(6): 1122-26, 2000.
8. Choueka, J., Heminger, H., Mass, D. P.: Cyclical testing of zone II flexor tendon repairs. *J Hand Surg (Am)* 25(6): 1127-34, 2000.
9. Hicks-Aldredge, K.: Ratite reproduction. *Vet Clin North Am Food Anim Pract.* 14(3): 437-53, 1998.
10. Martinez-Diaz, R. A., Herrera, S., Castro, A., Ponce, F.: *Entamoeba* sp. (Sarcocystidophora: Endamoebidae) from ostriches (*Struthio camelus*) (Aves: Struthionidae). *Vet Parasitol.* 92(3): 173-9, 2000.
11. Wagner, W. M., Kirberger, R. M.: Radiography of the thoraco-abdominal cavity of the ostrich (*Struthio camelus*). *Vet Radiol Ultrasound* 42(2): 134-40, 2001.
12. Bezuidenhout, A. J.: The coronary circulation of the heart of the ostrich (*Struthio camelus*). *J Anat.* 138(3): 385-97, 1984.